

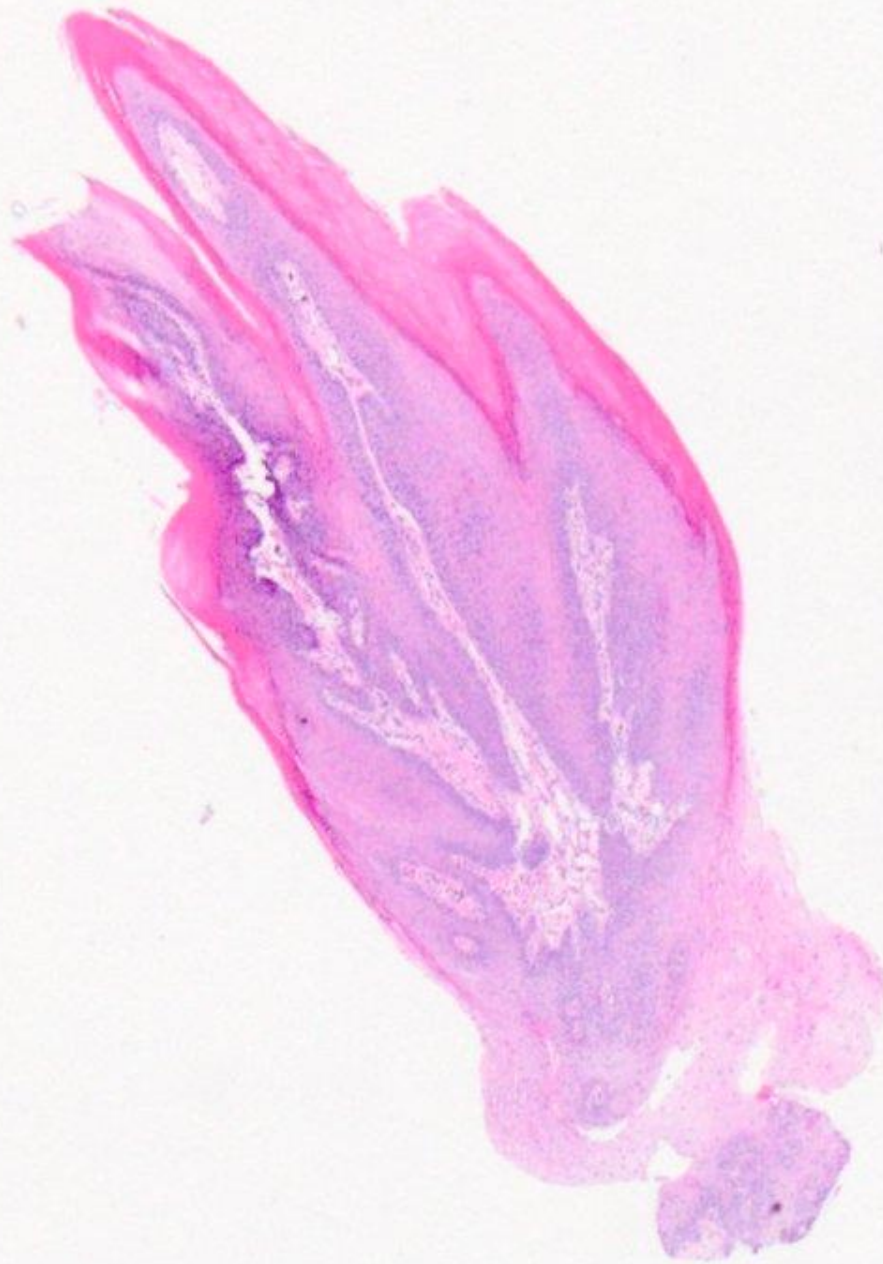
# Oral Histopathology

## Series 11

**DAVID E. KLINGMAN, DMD**

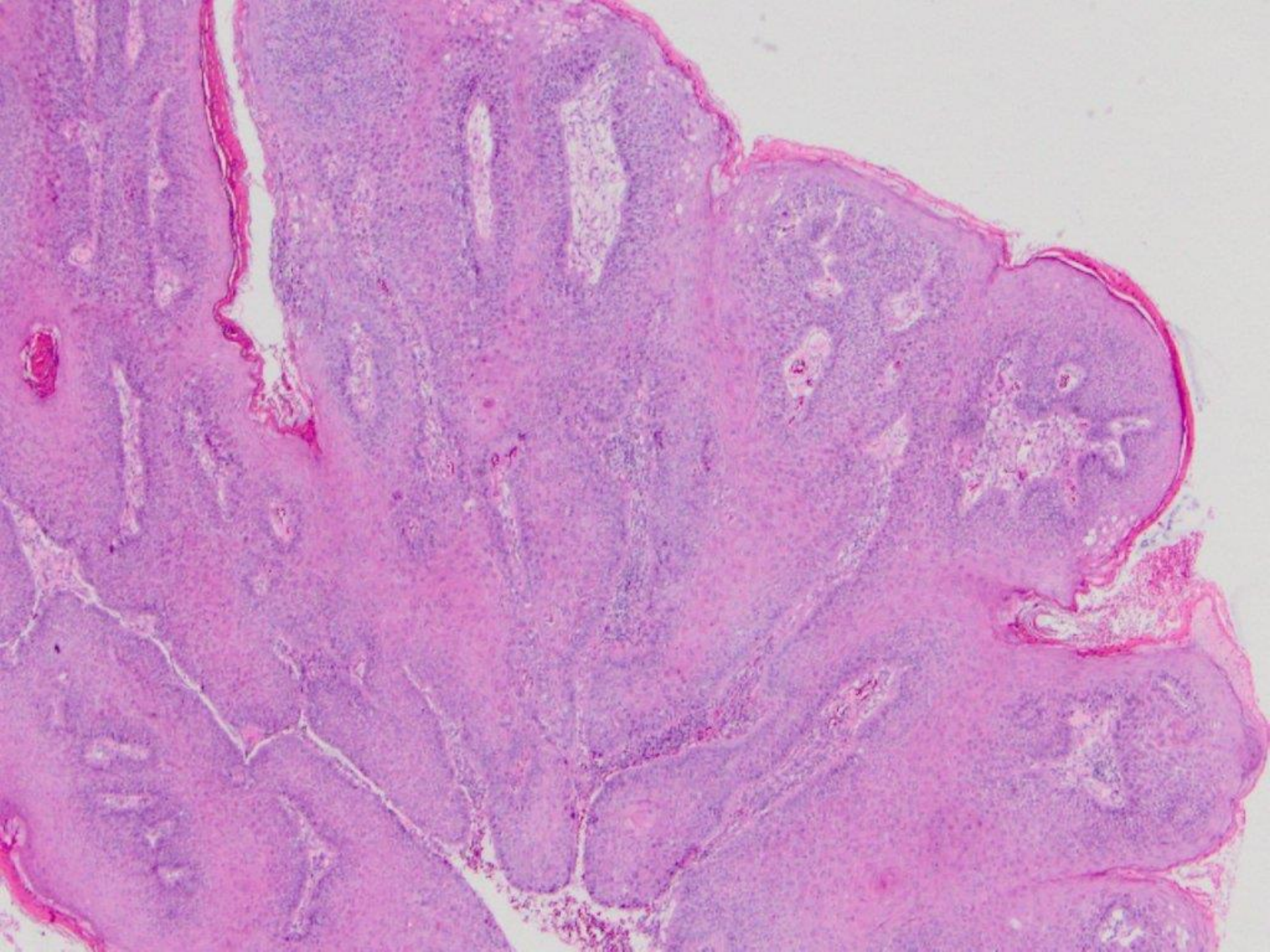
*Diplomate, American Board of Oral and Maxillofacial Pathology*

*Diplomate, American Board of General Dentistry*

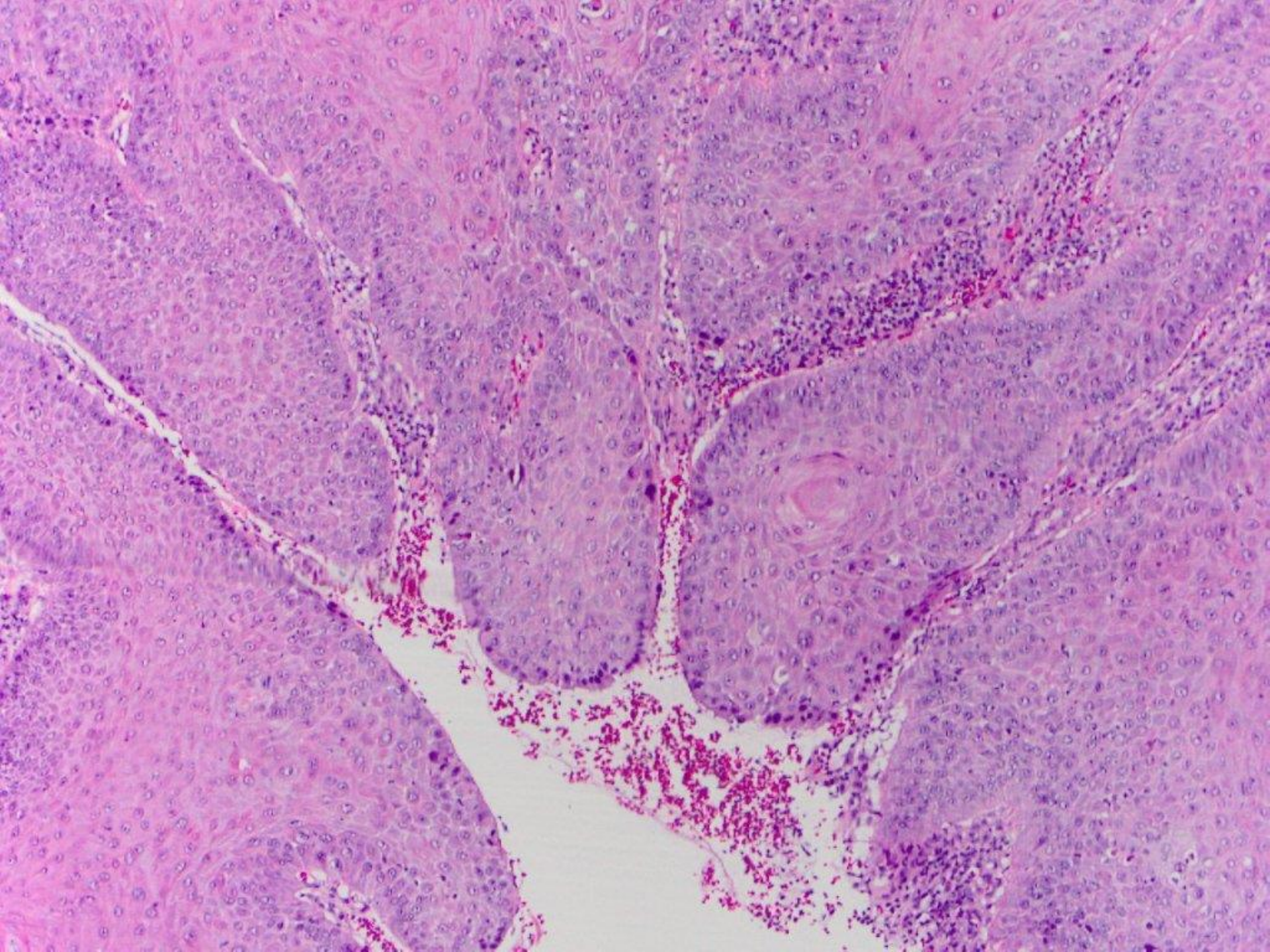


squamous papilloma

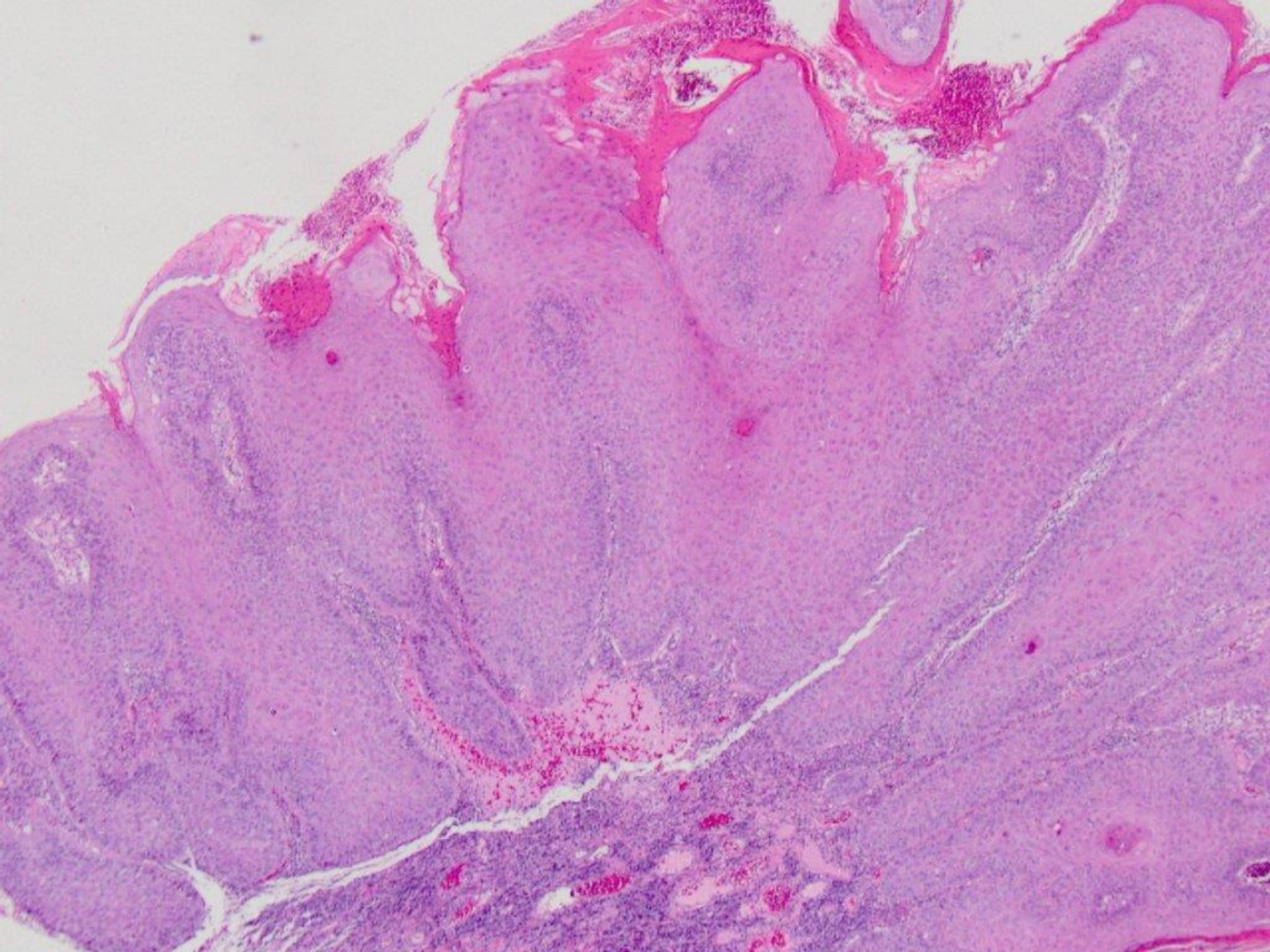




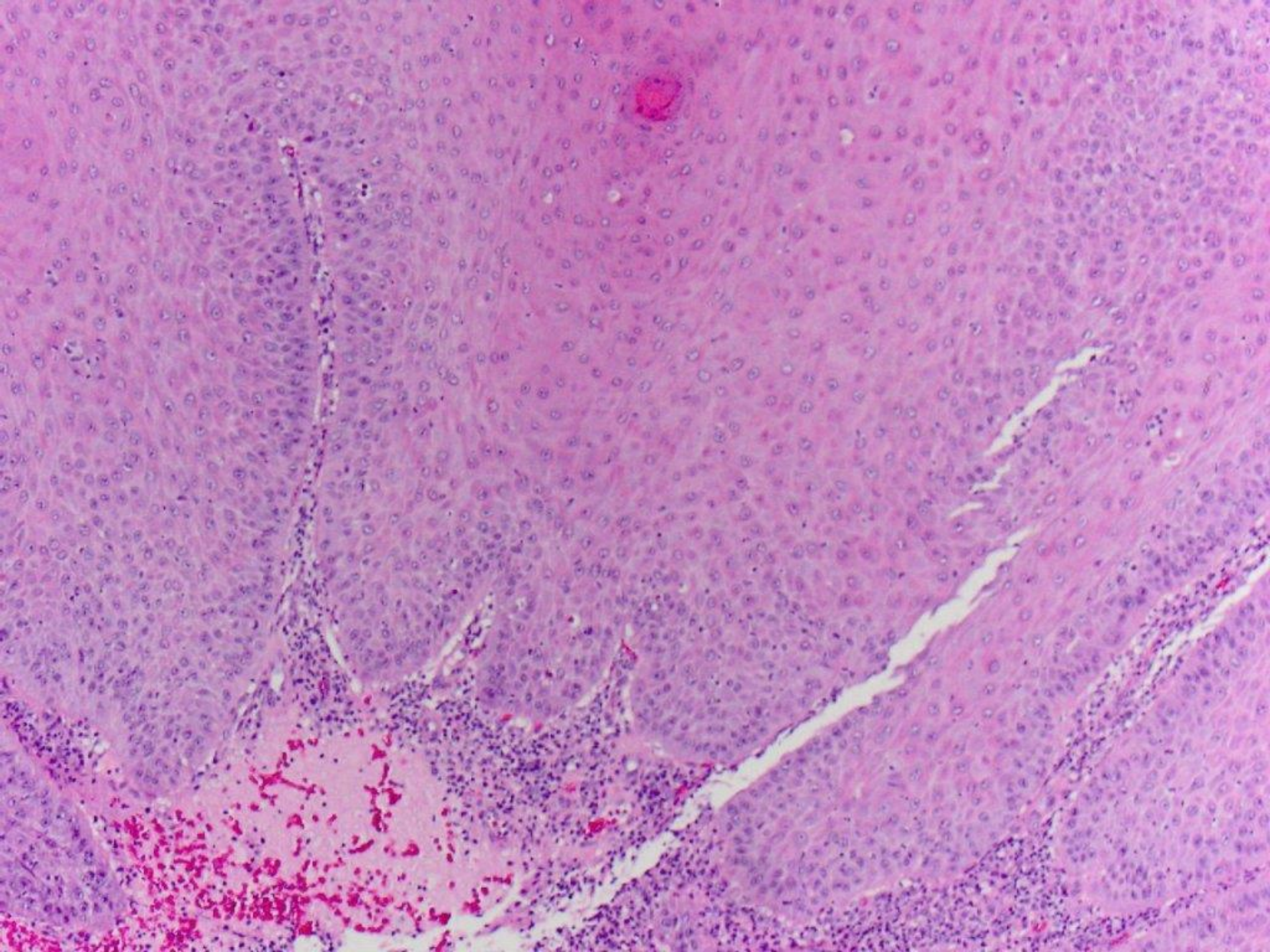




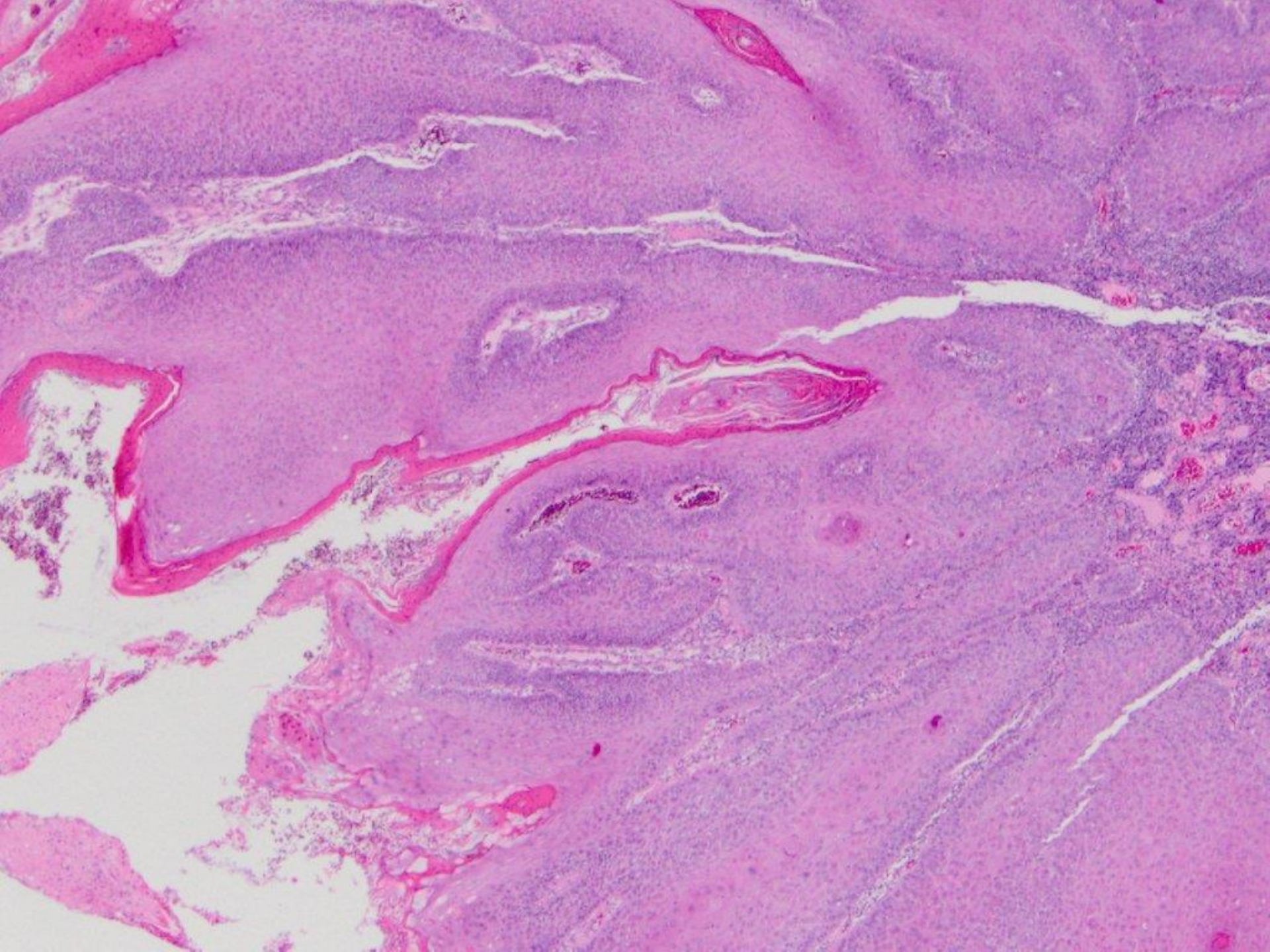




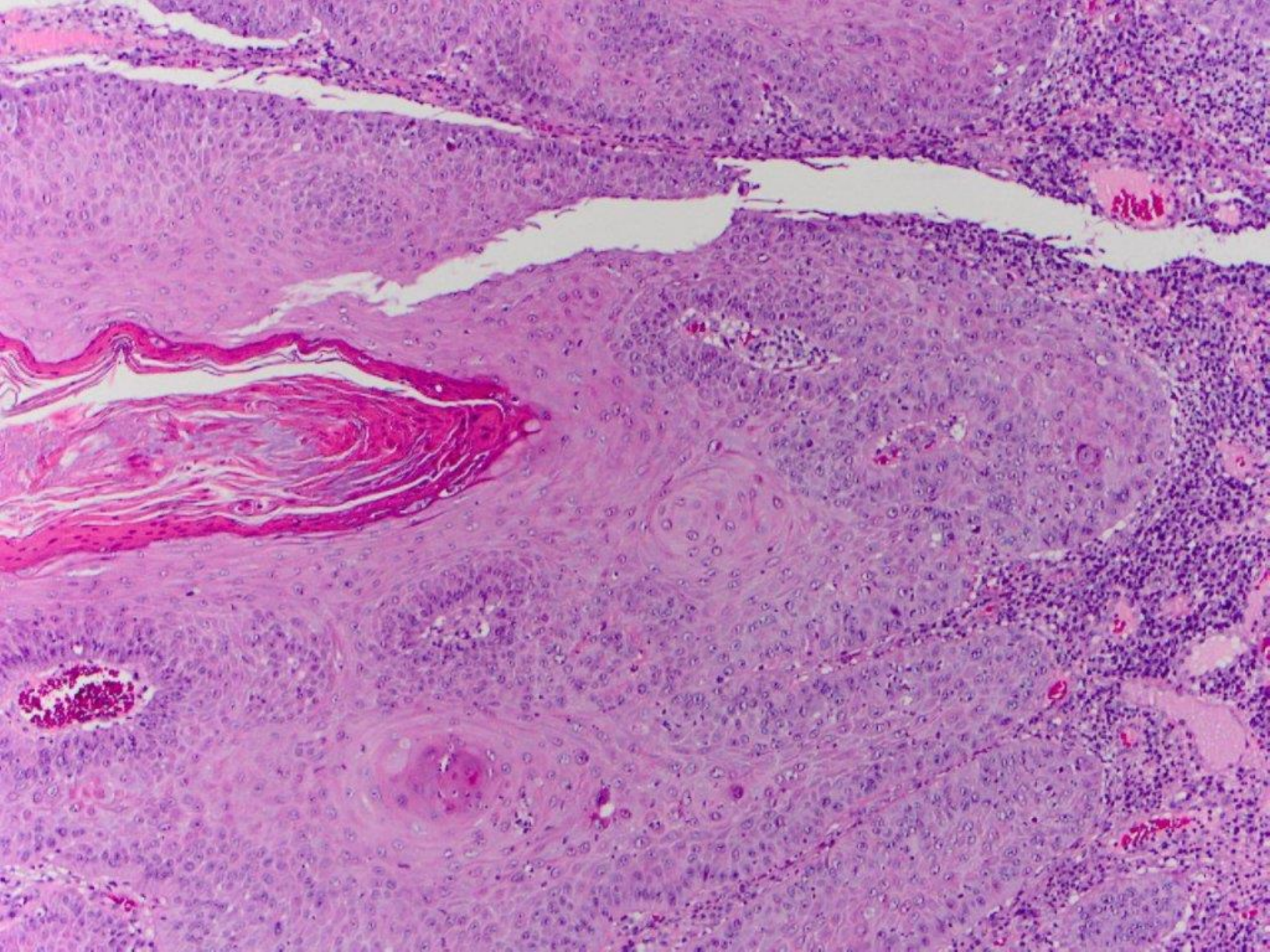




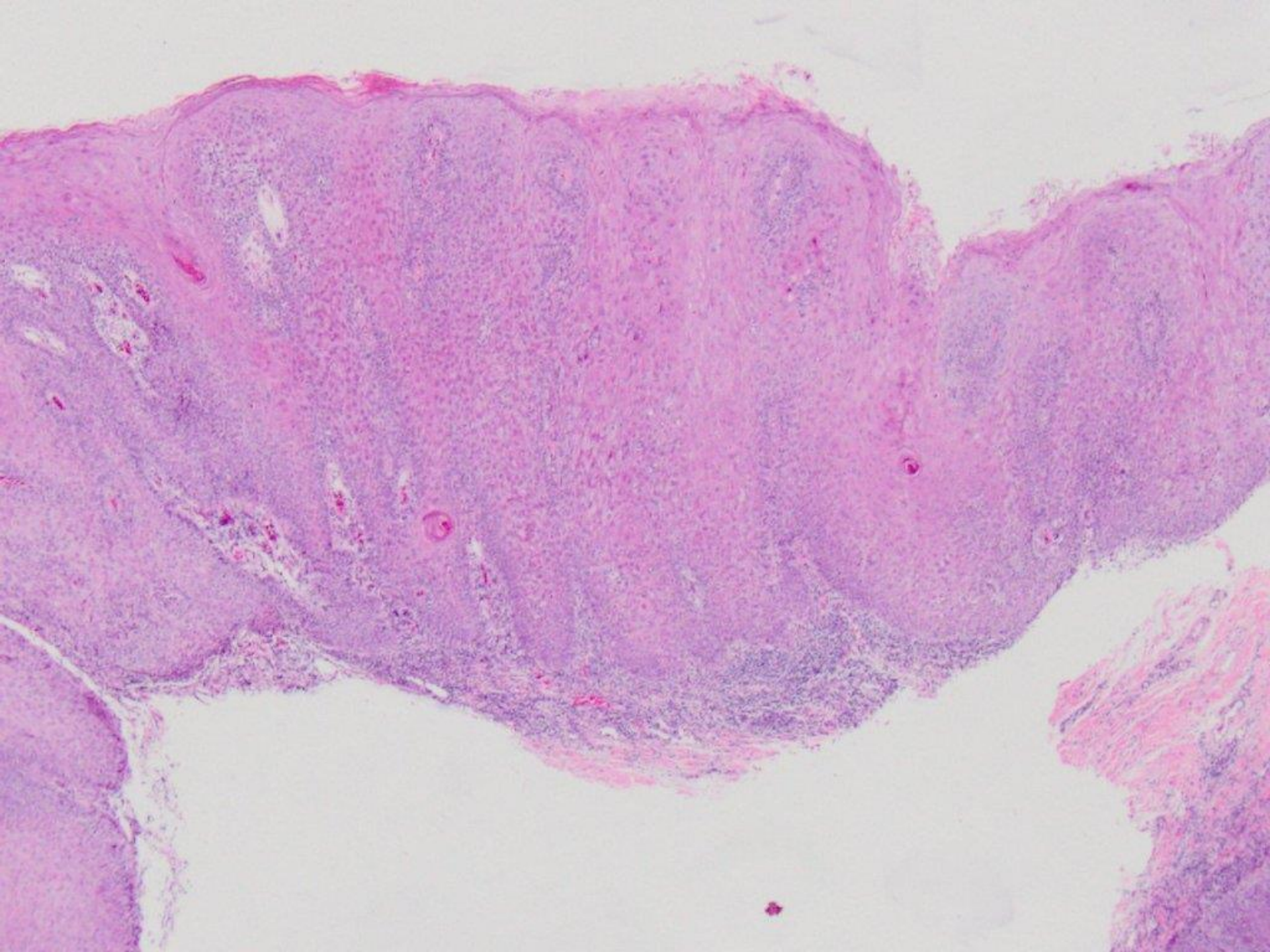




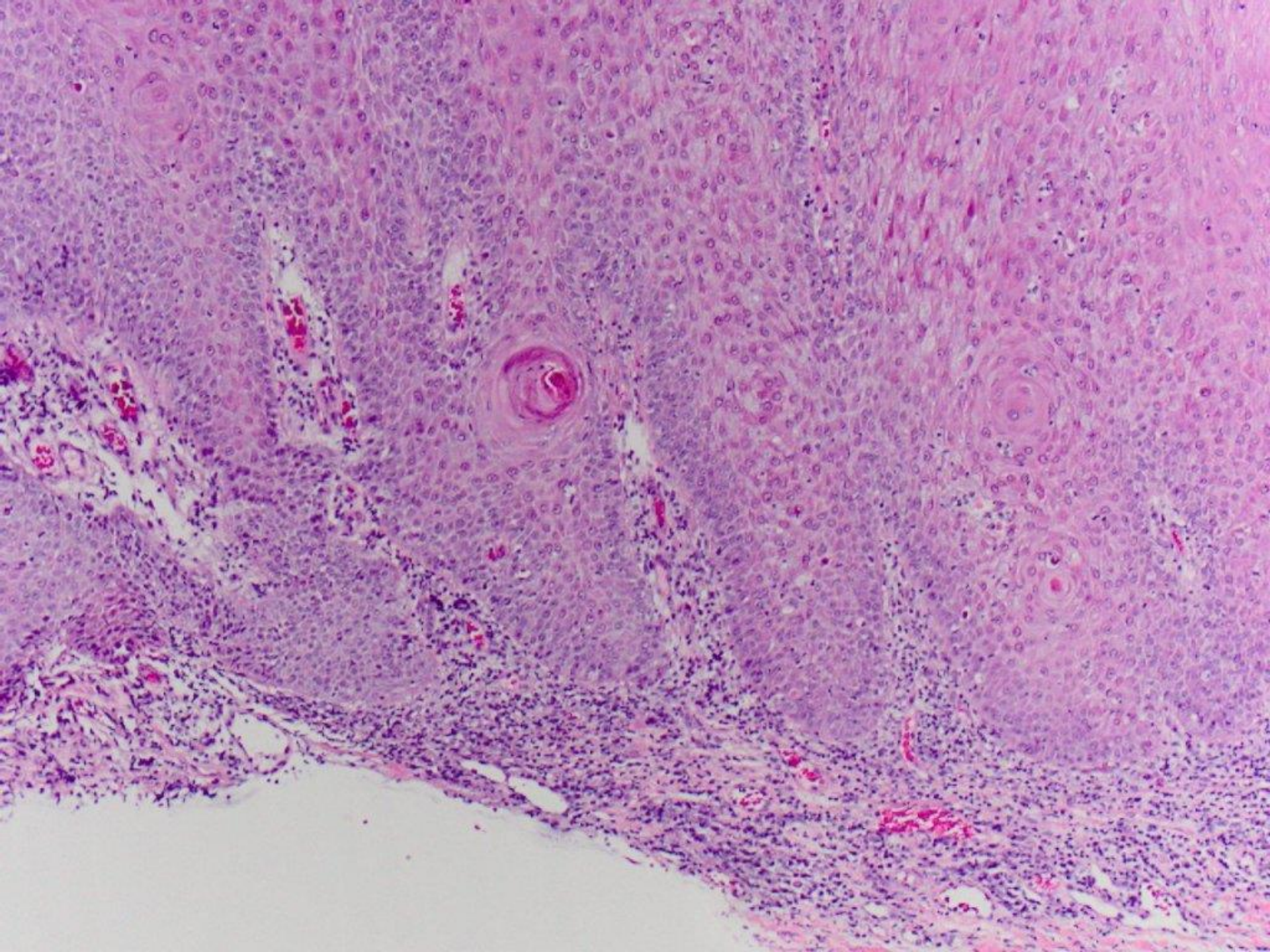




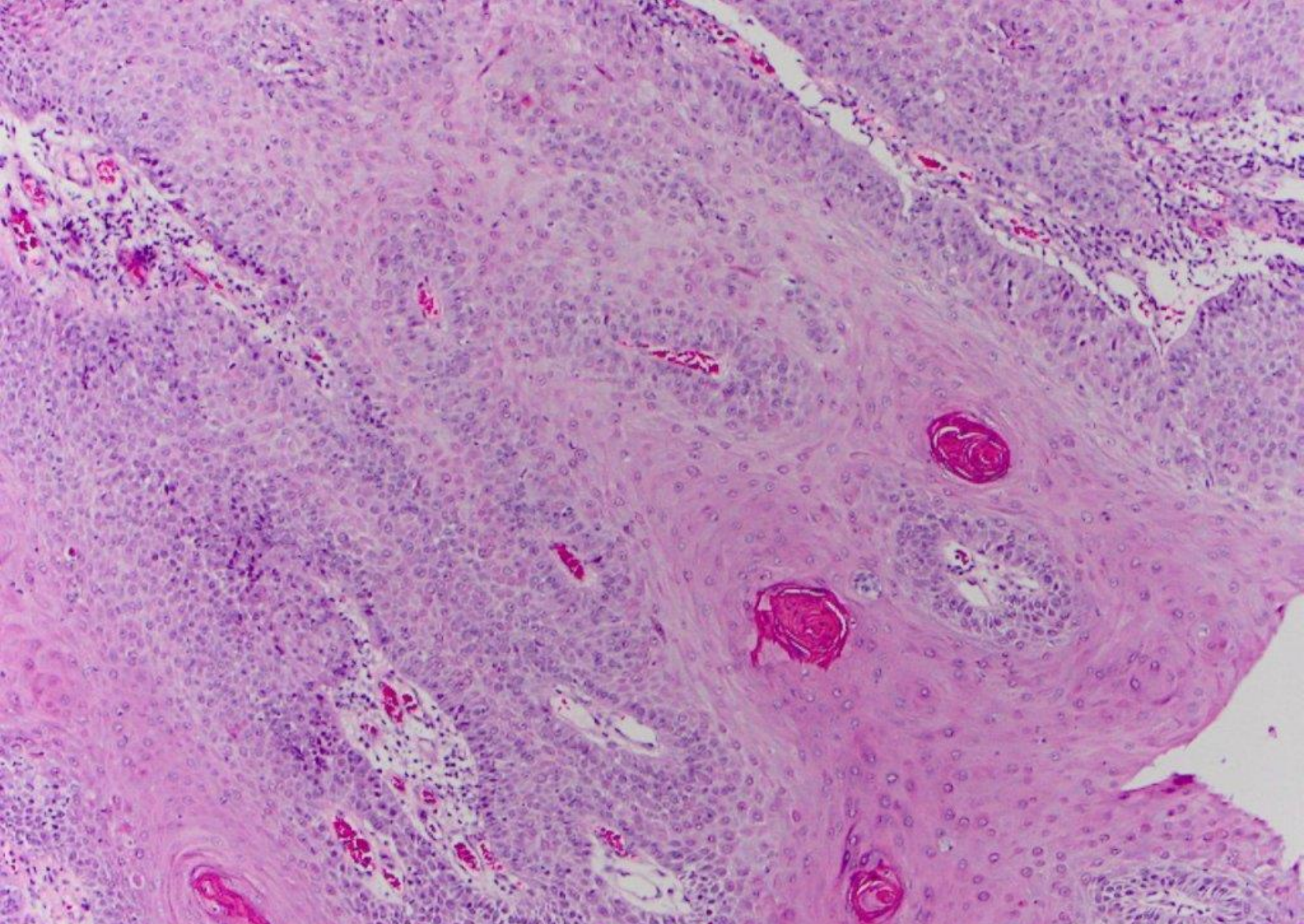






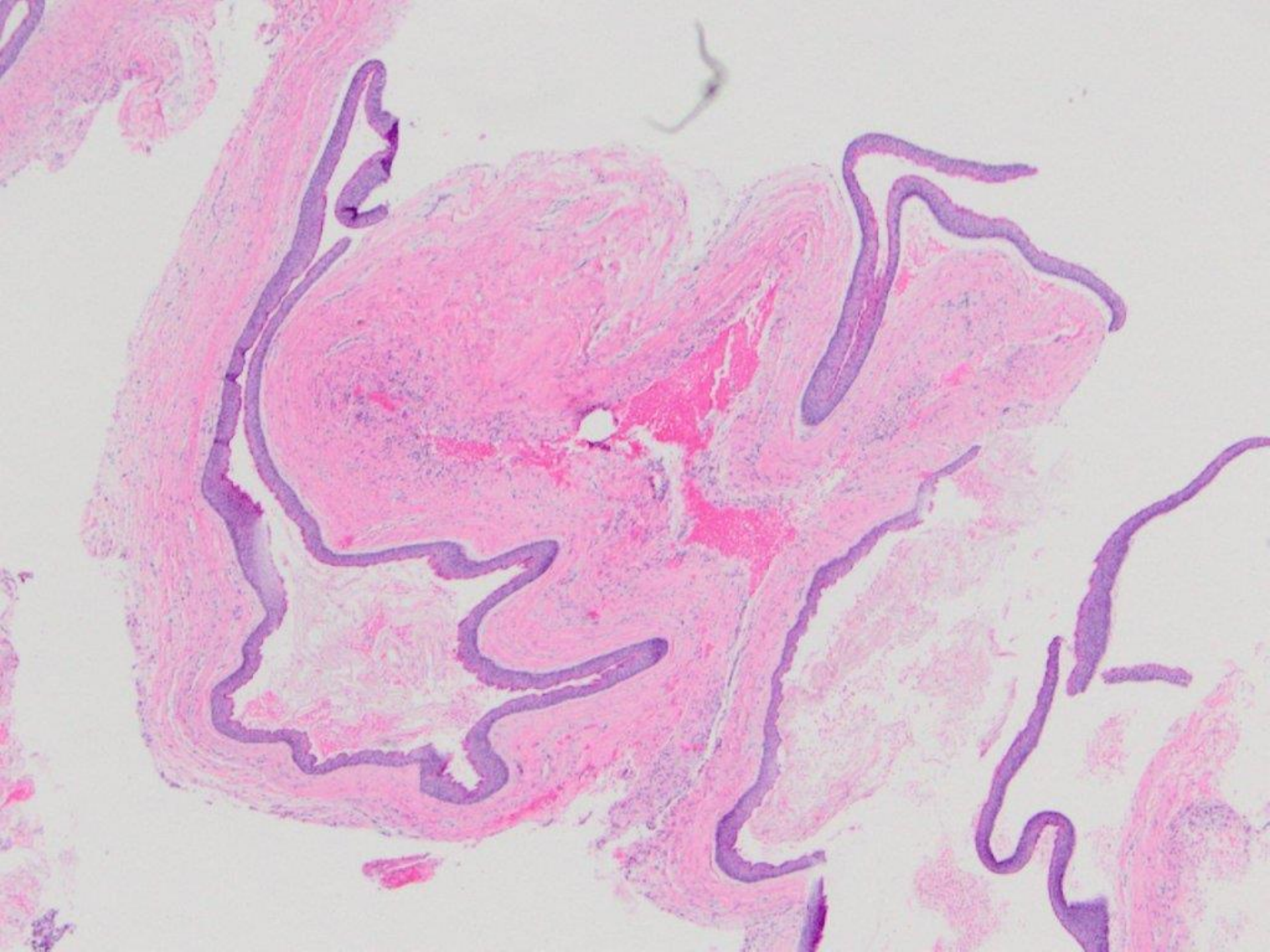




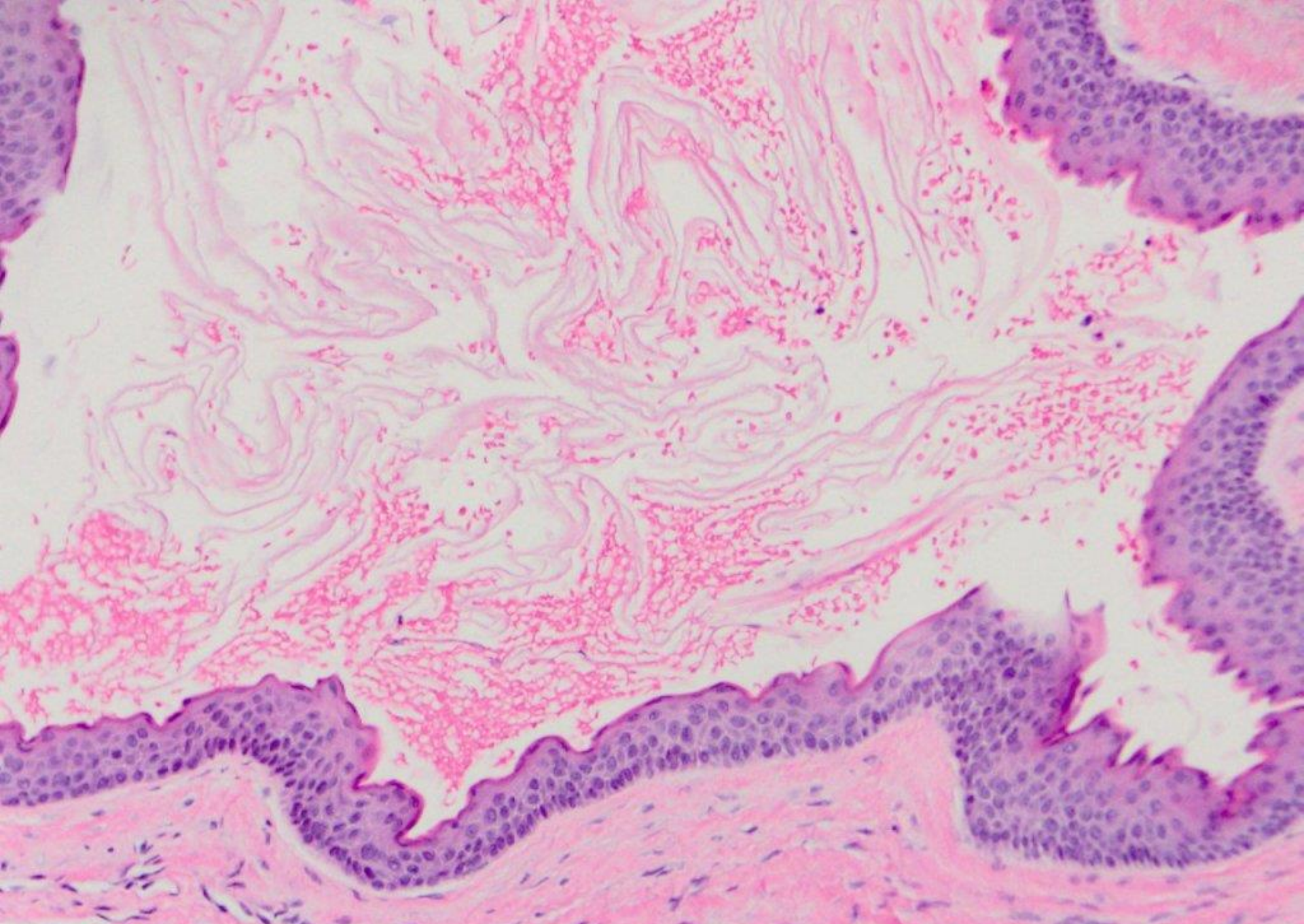


verrucous carcinoma



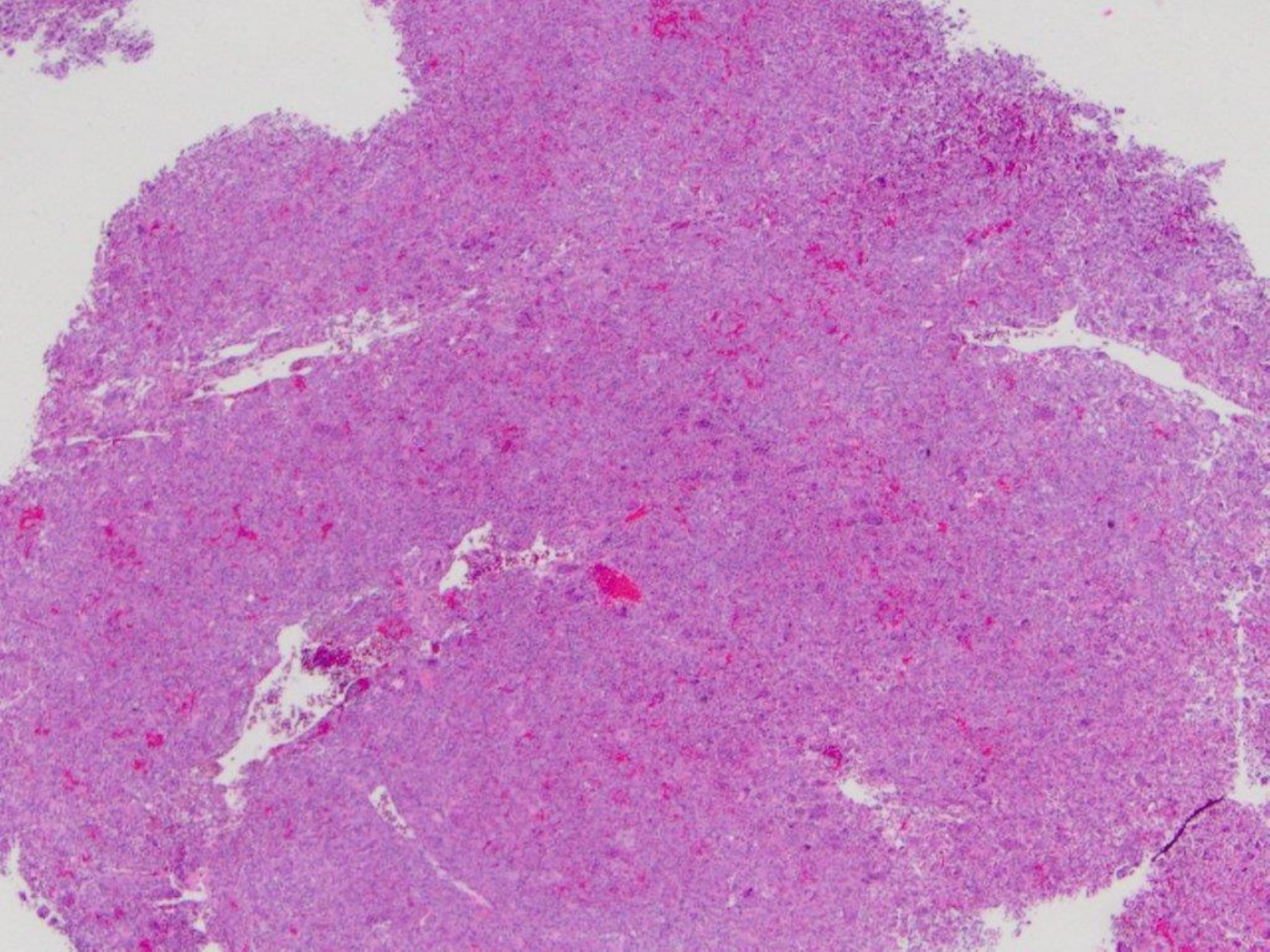




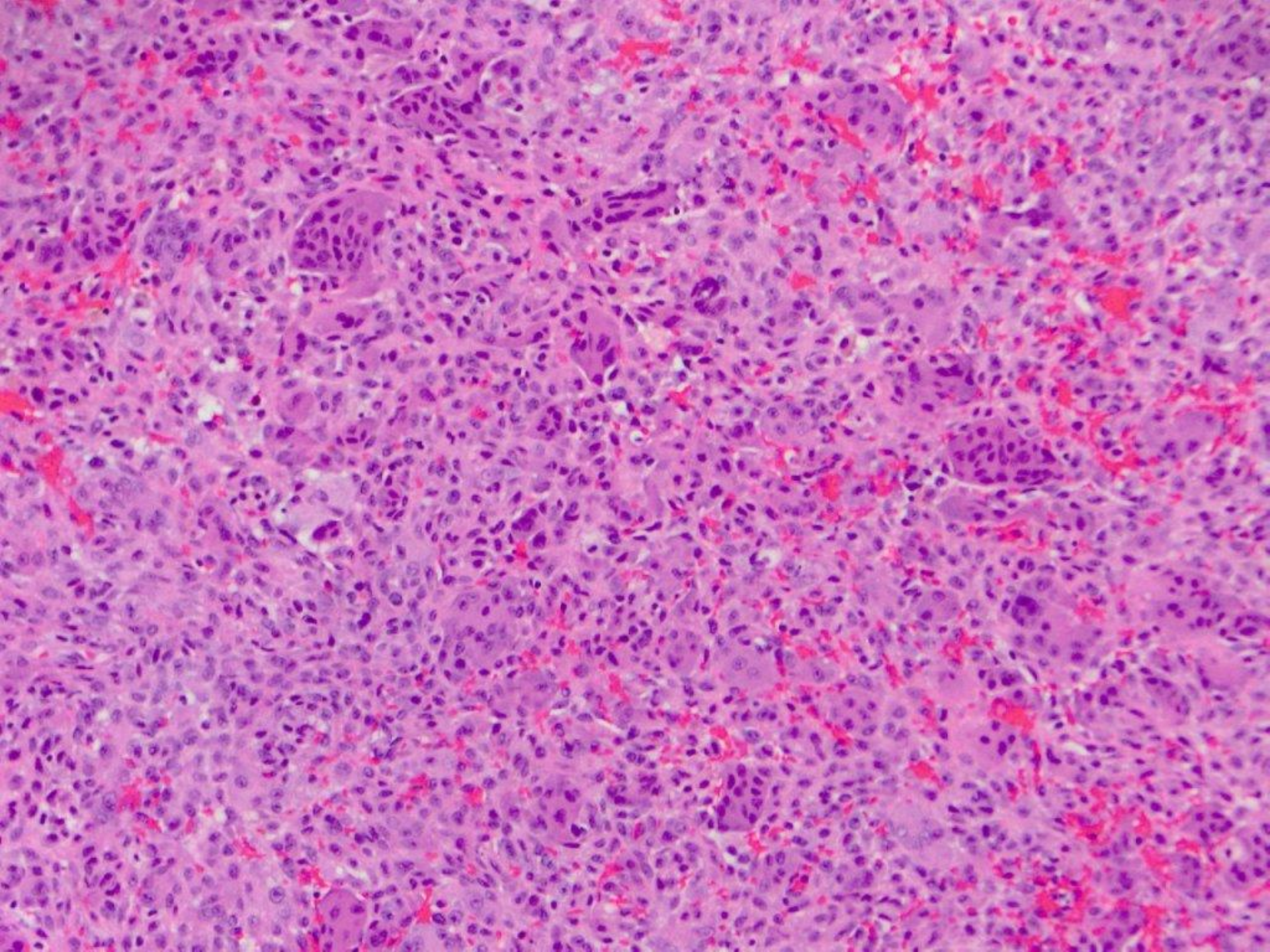


odontogenic keratocyst (keratocystic odontogenic tumor)

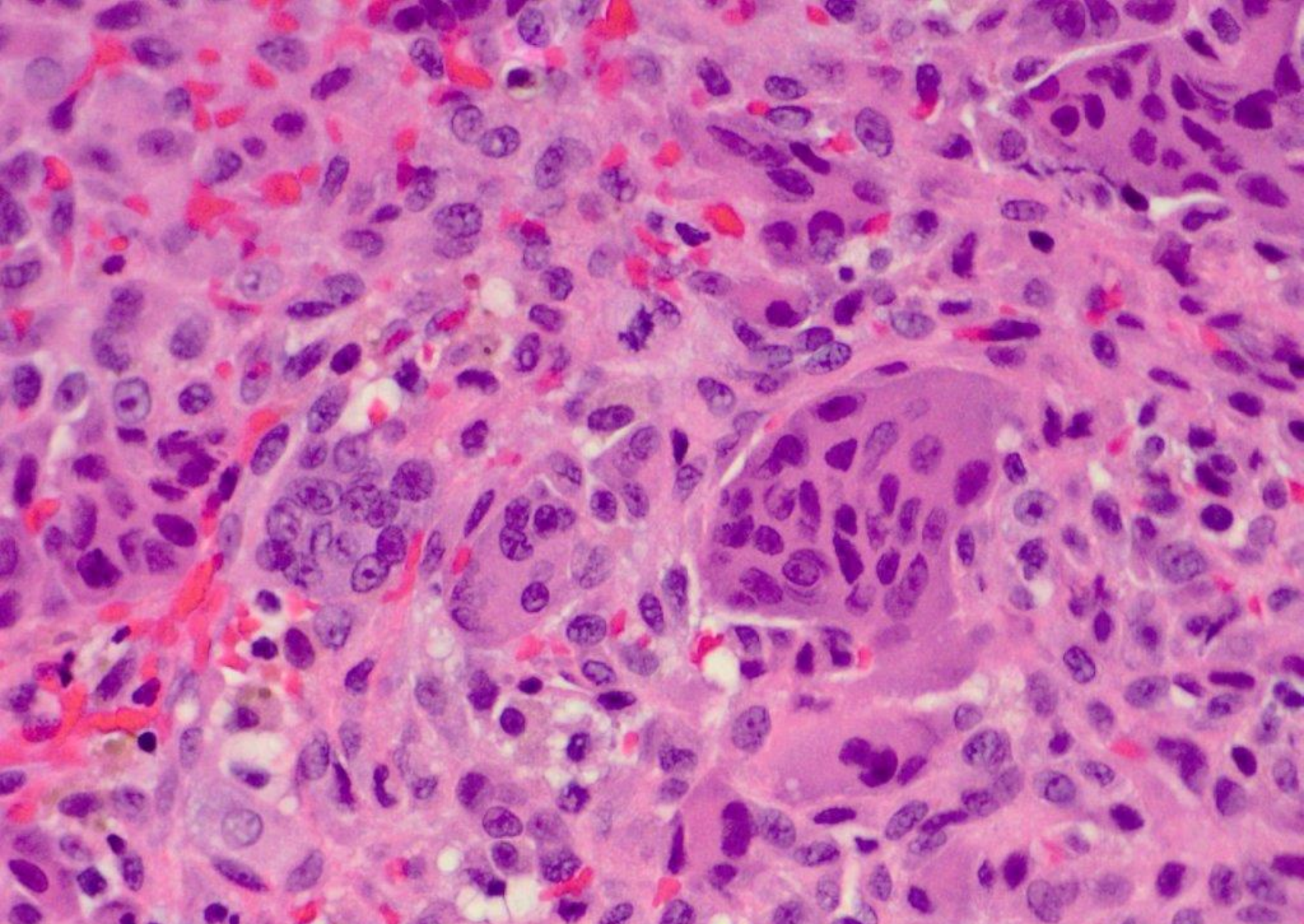






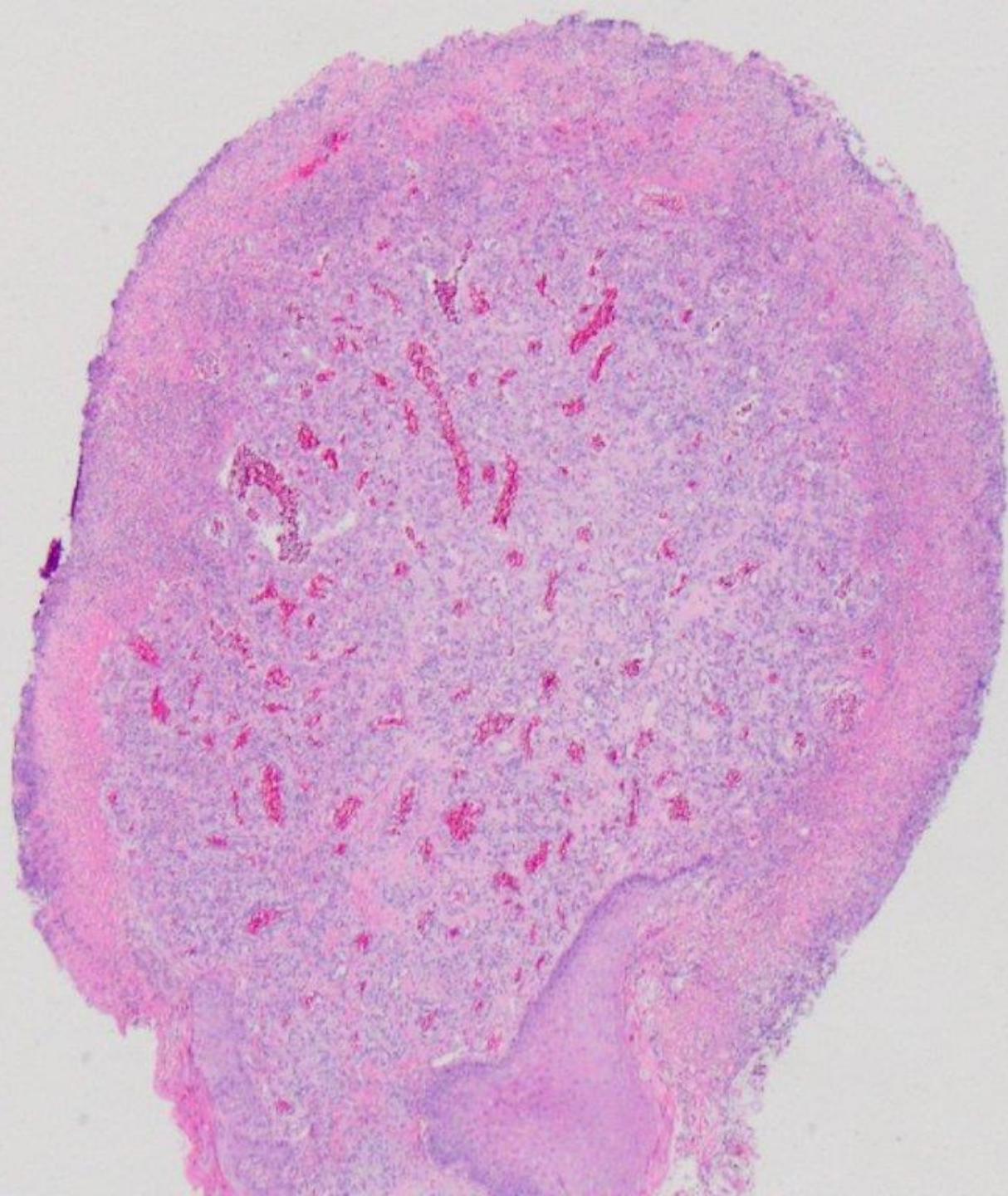




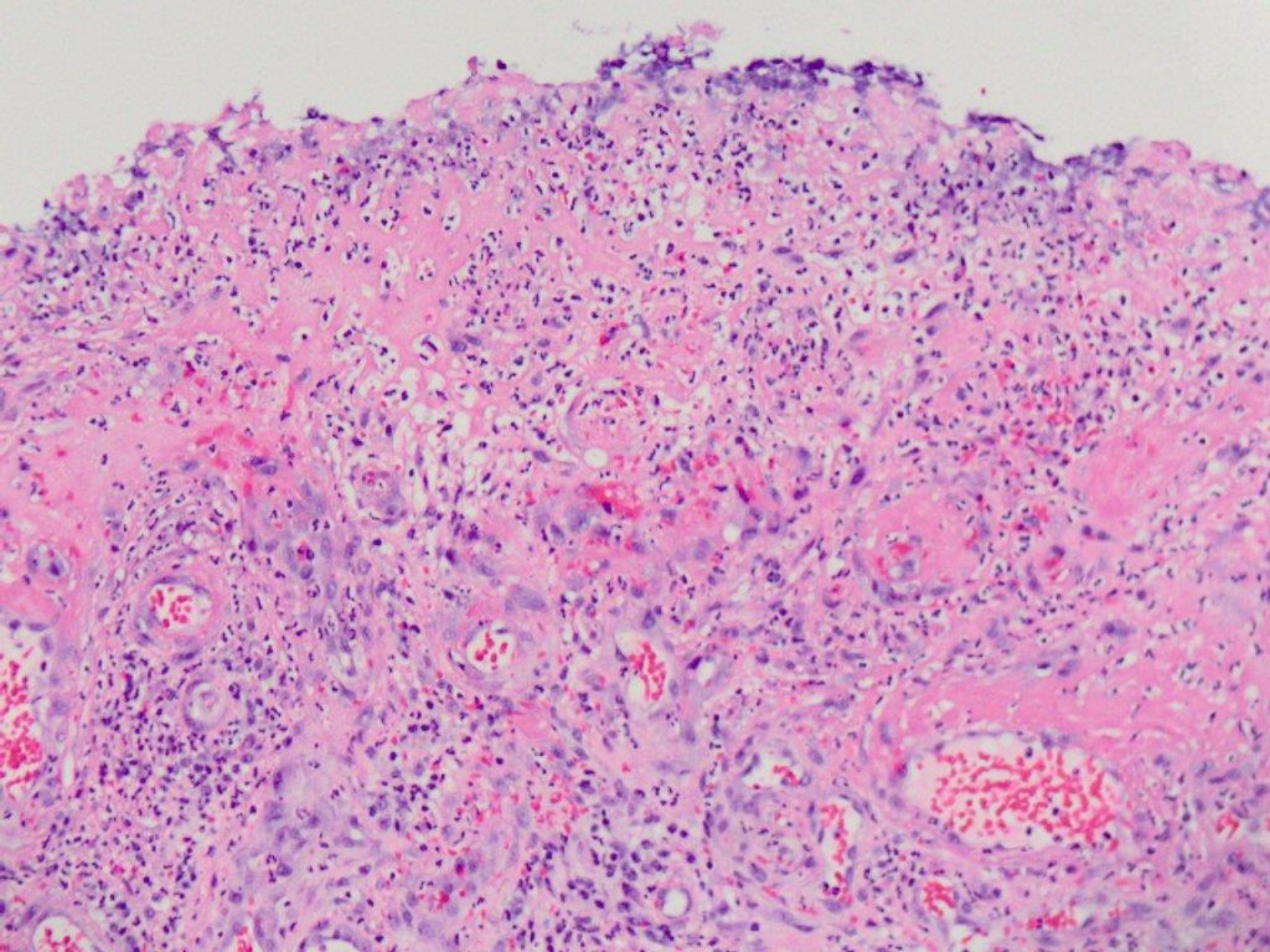


(central) giant cell granuloma

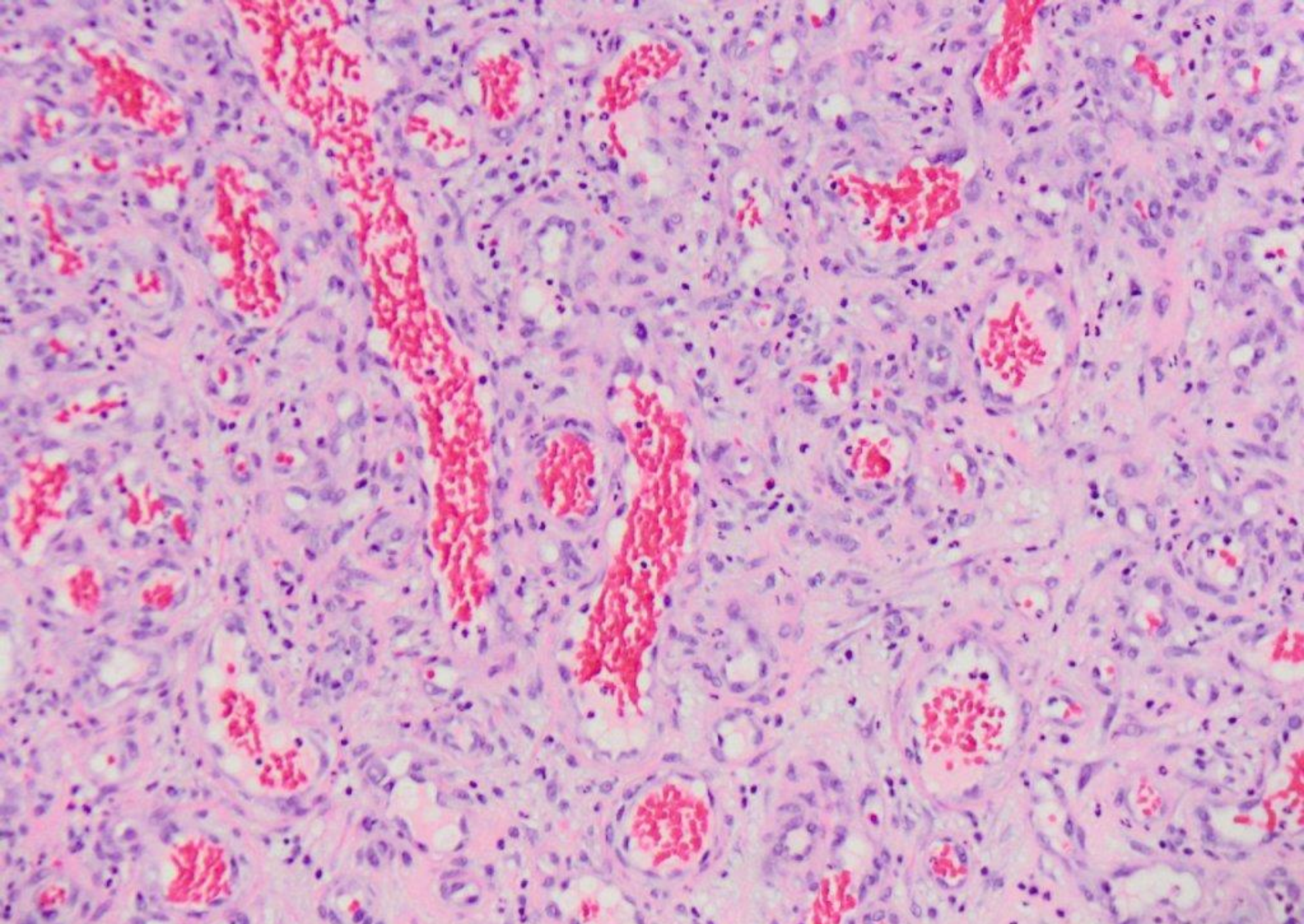






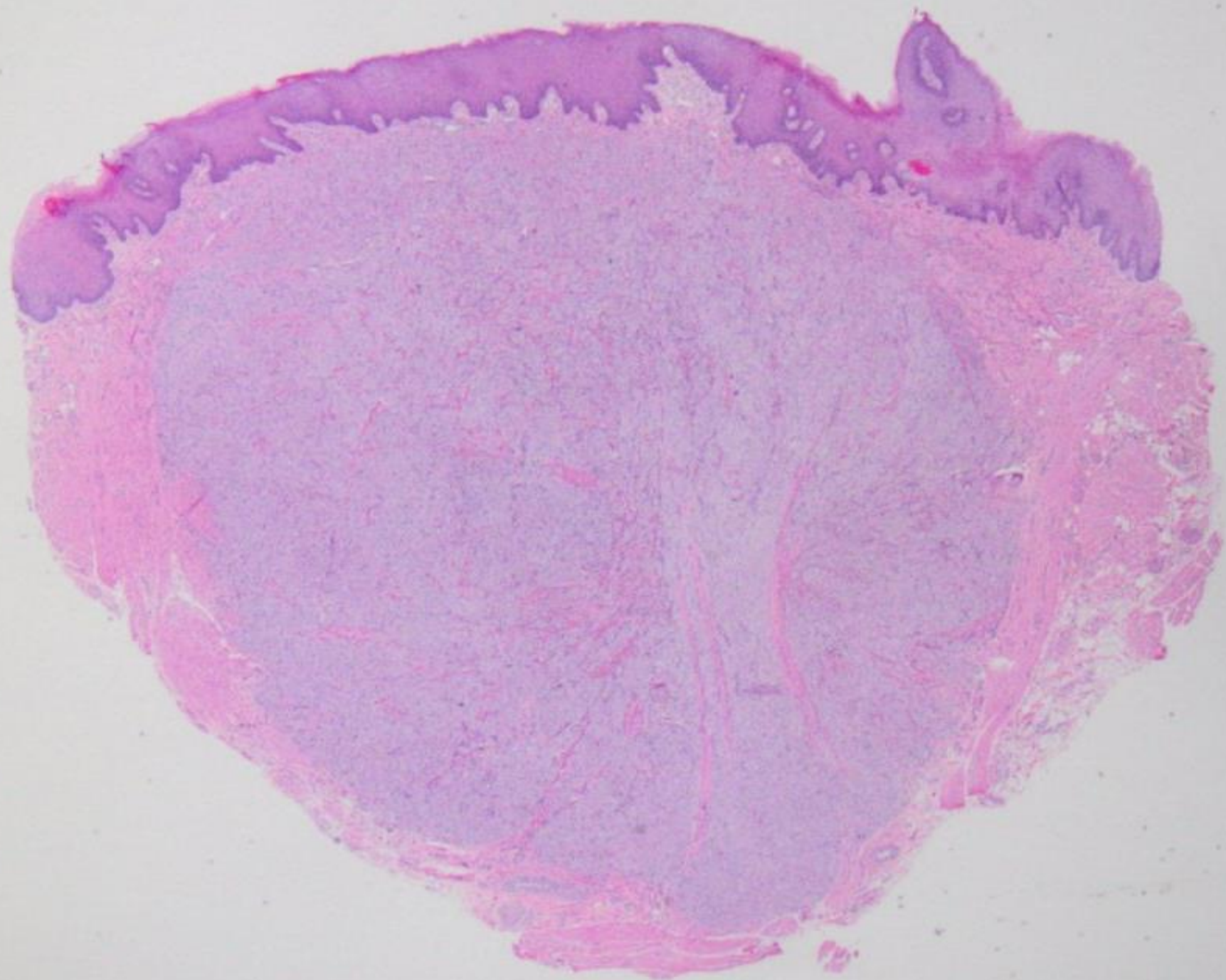




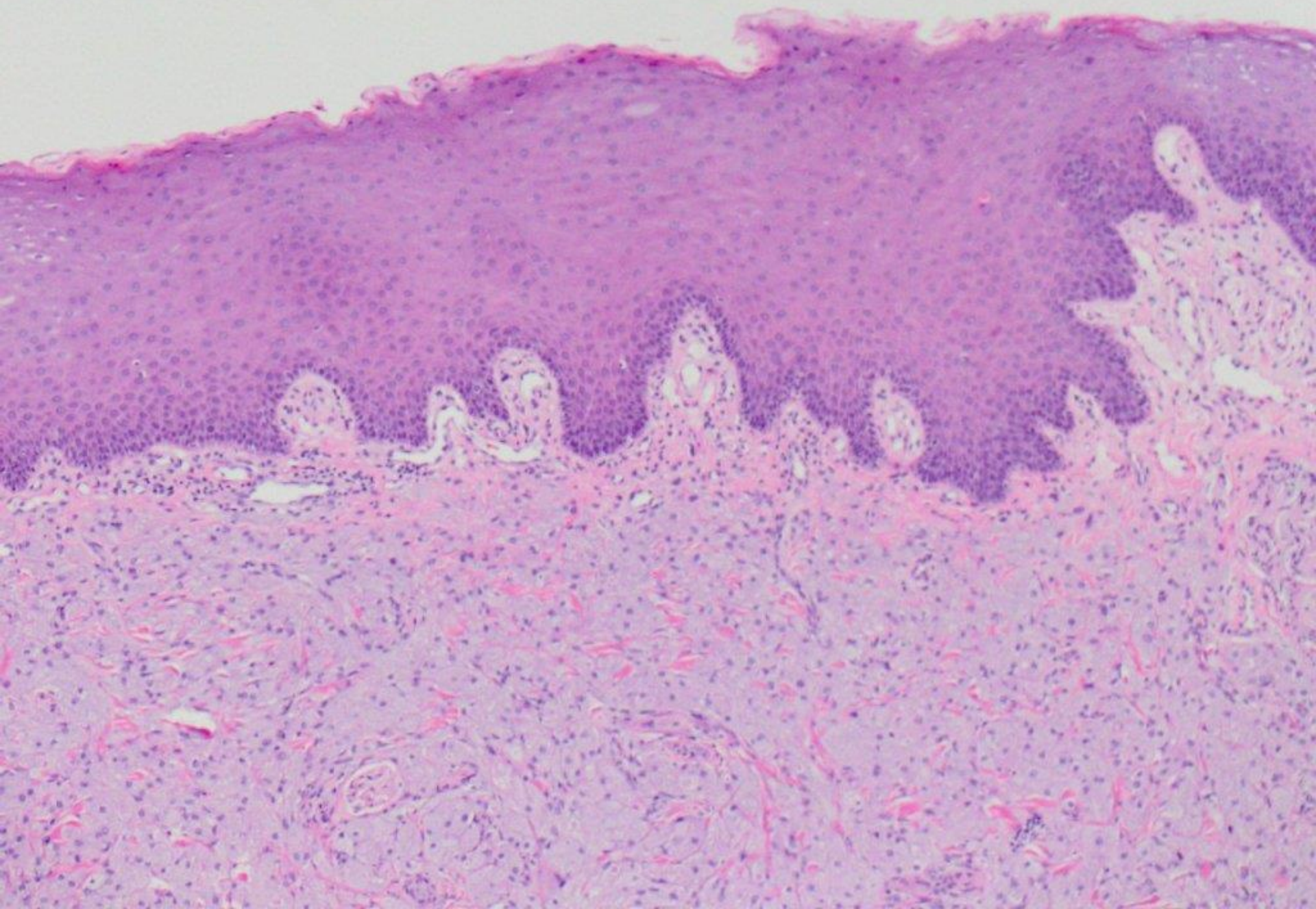


ulcerated pyogenic granuloma

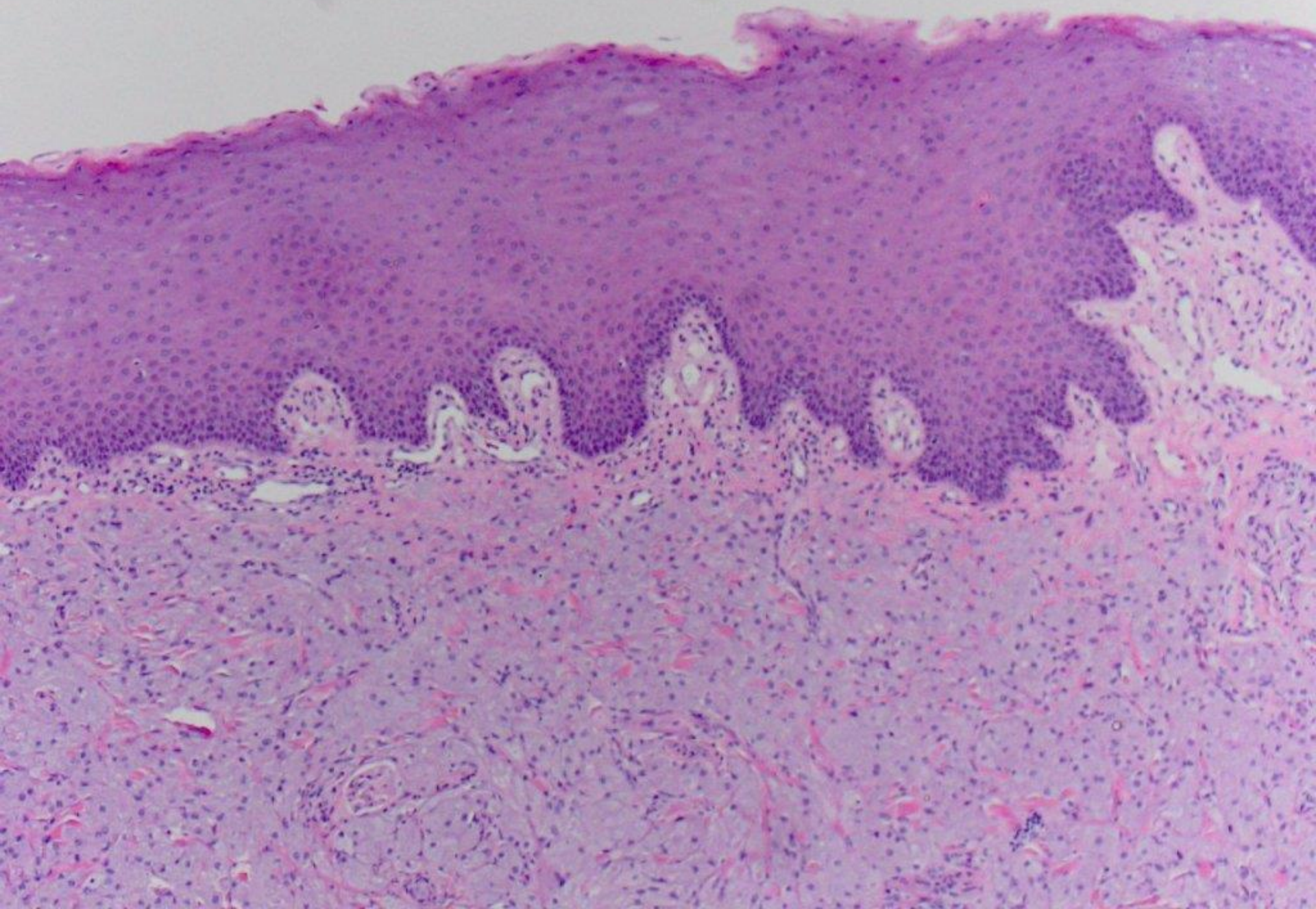




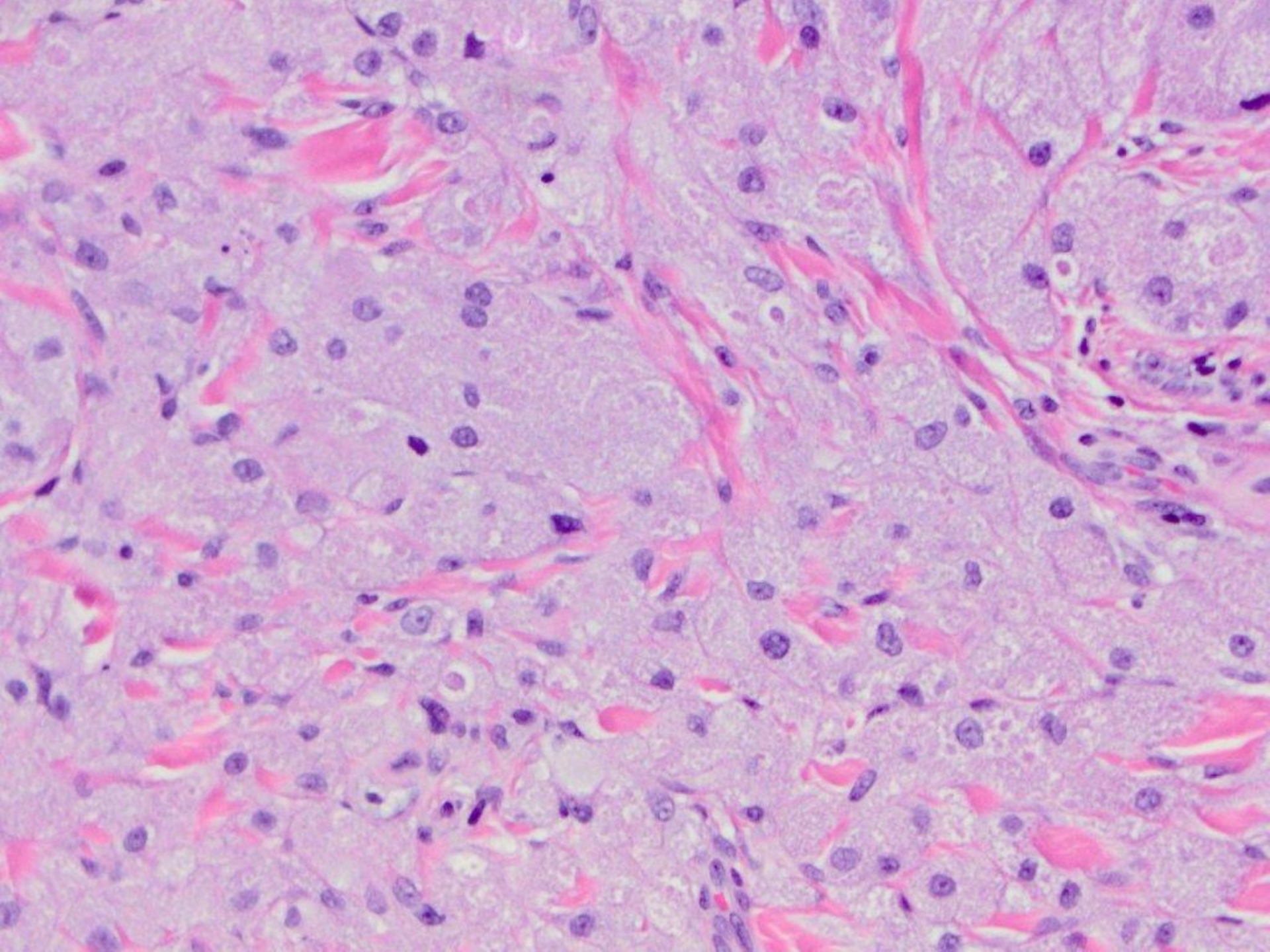




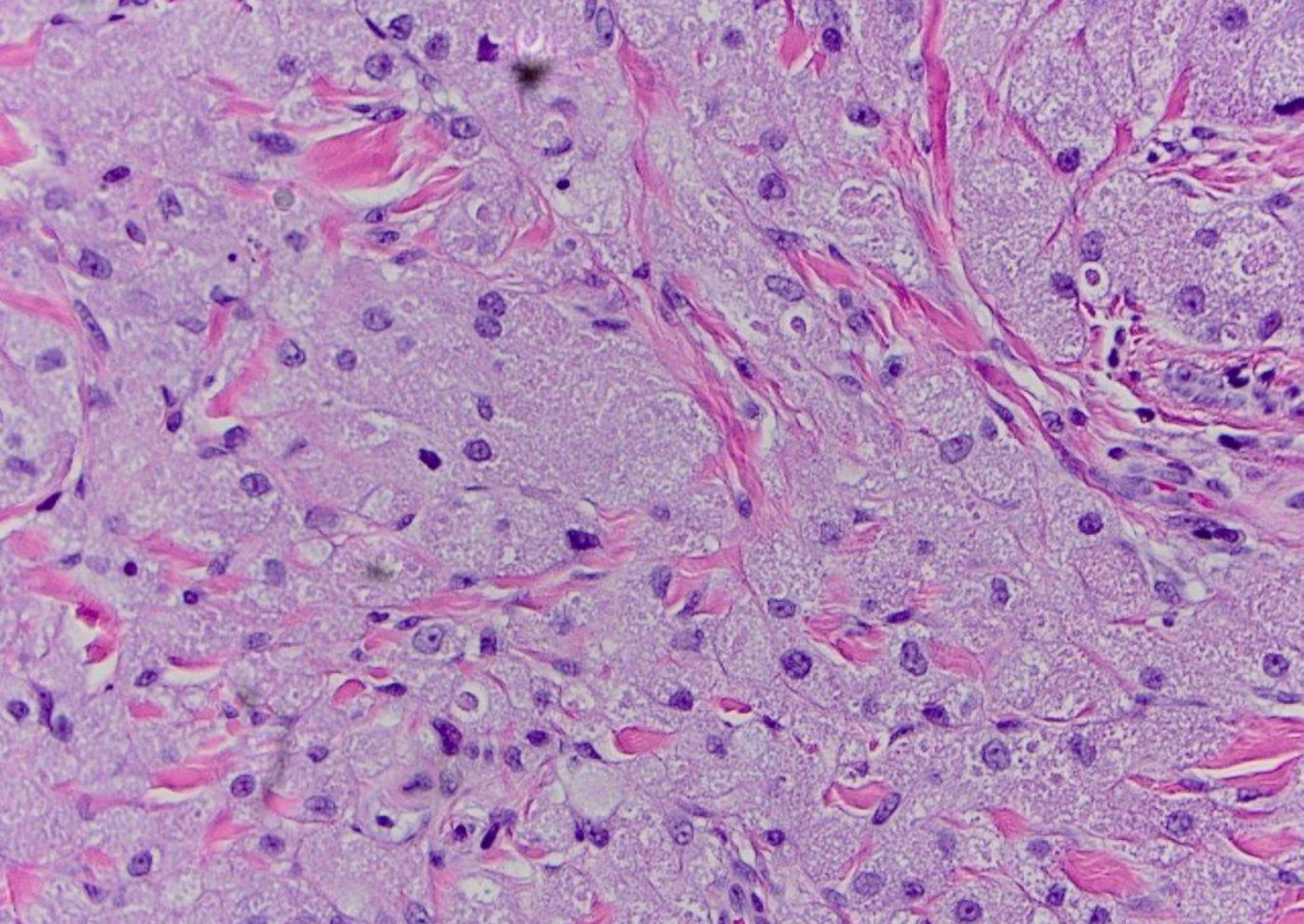






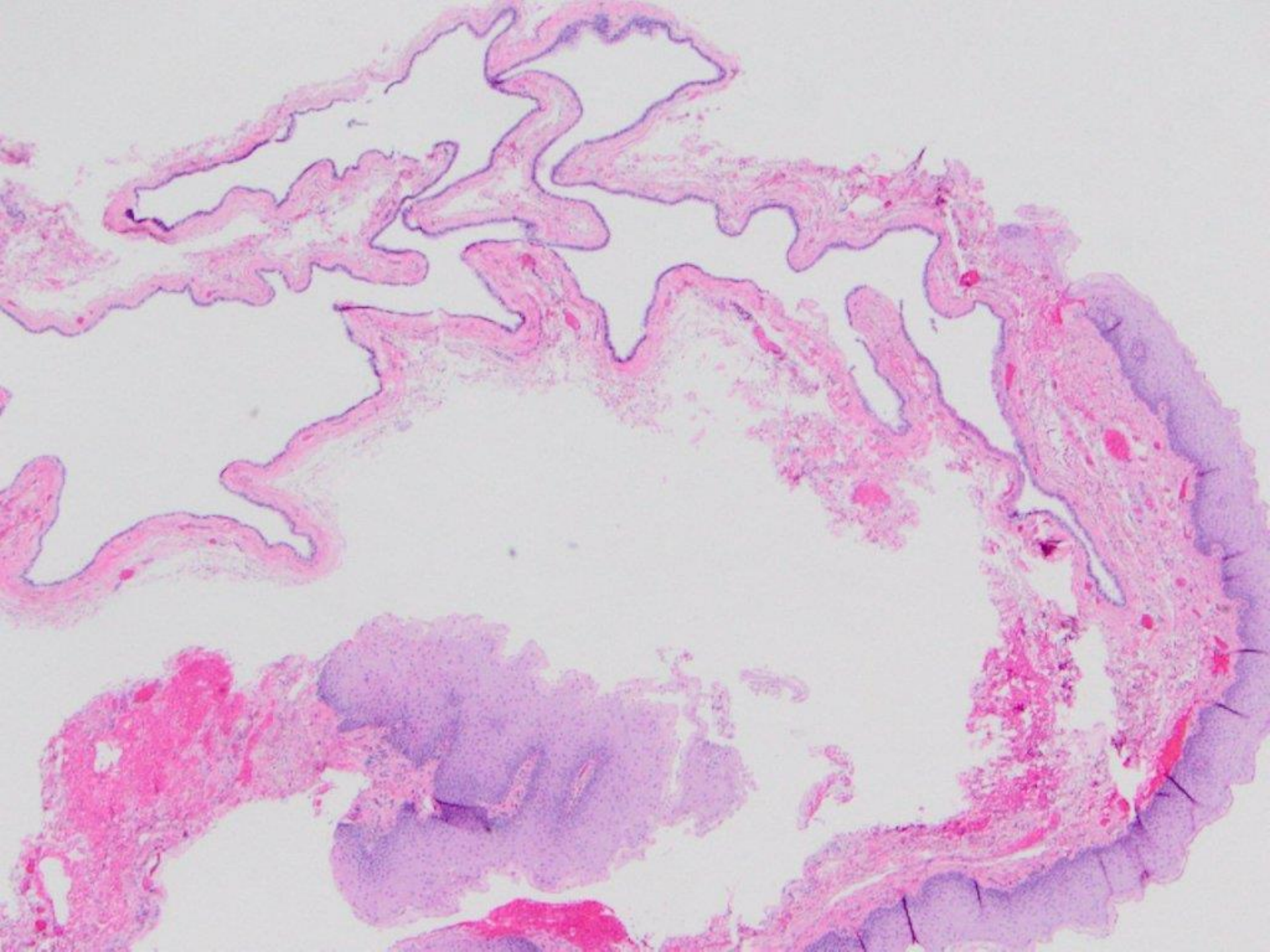




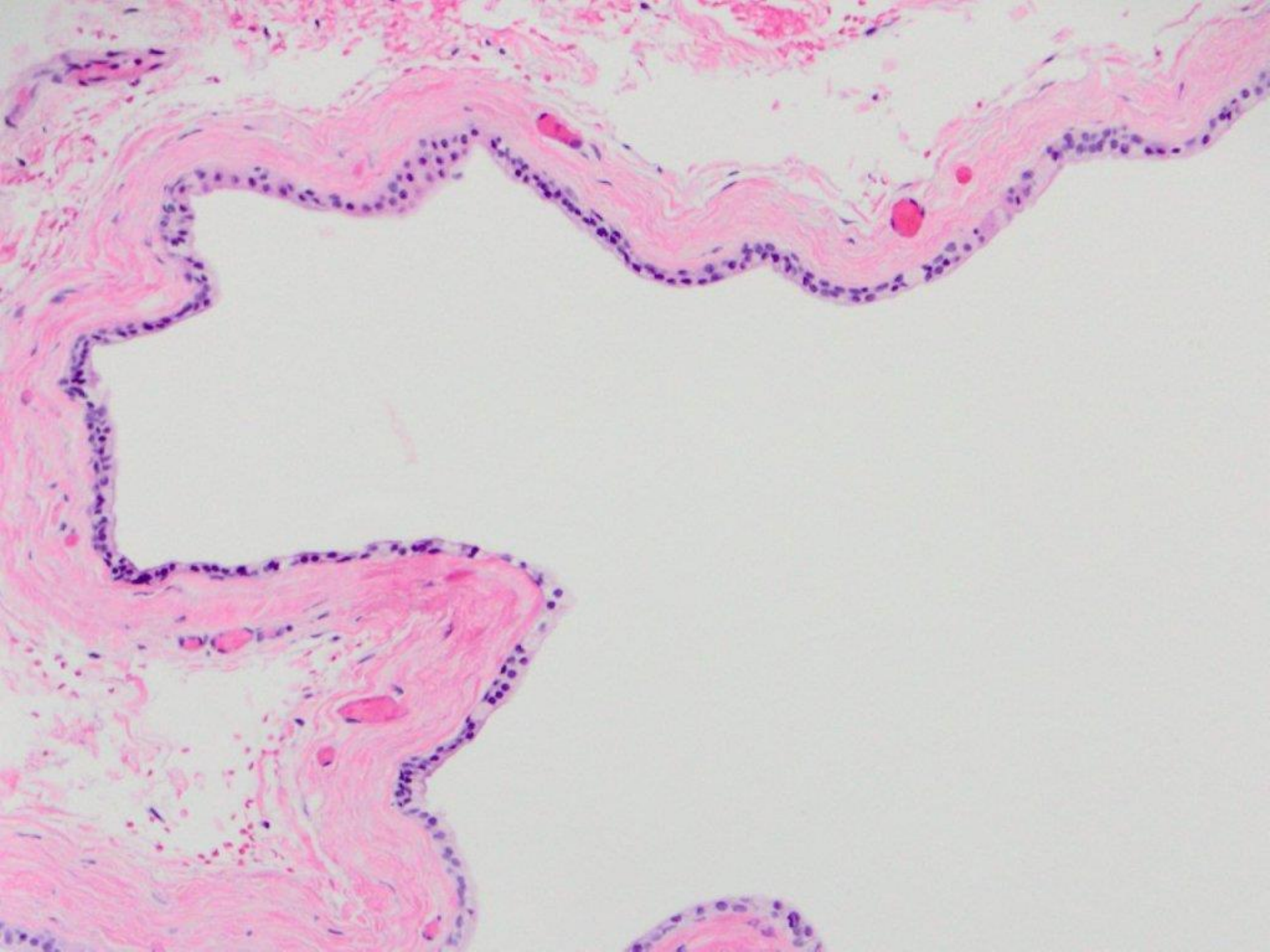


granular cell tumor

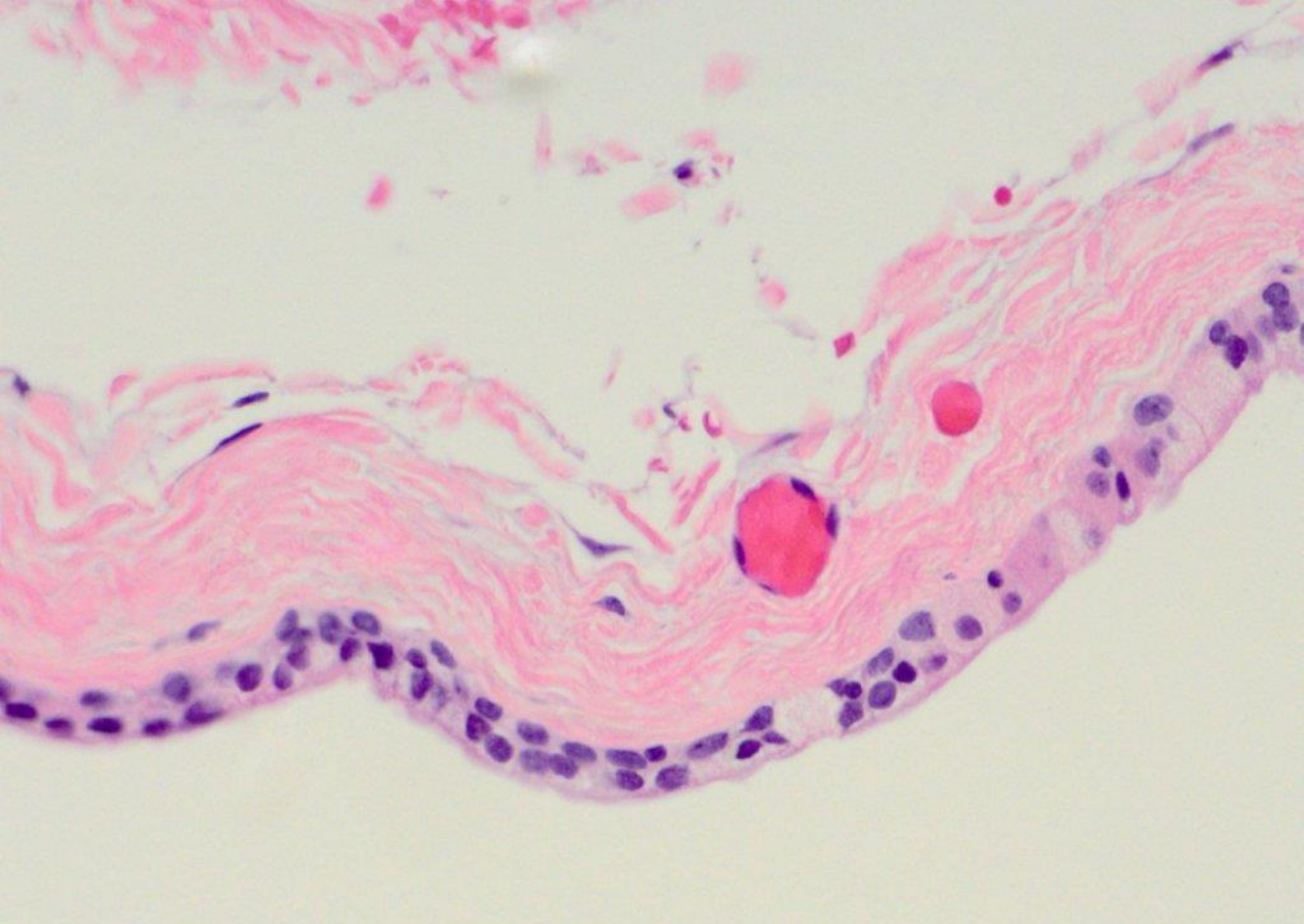






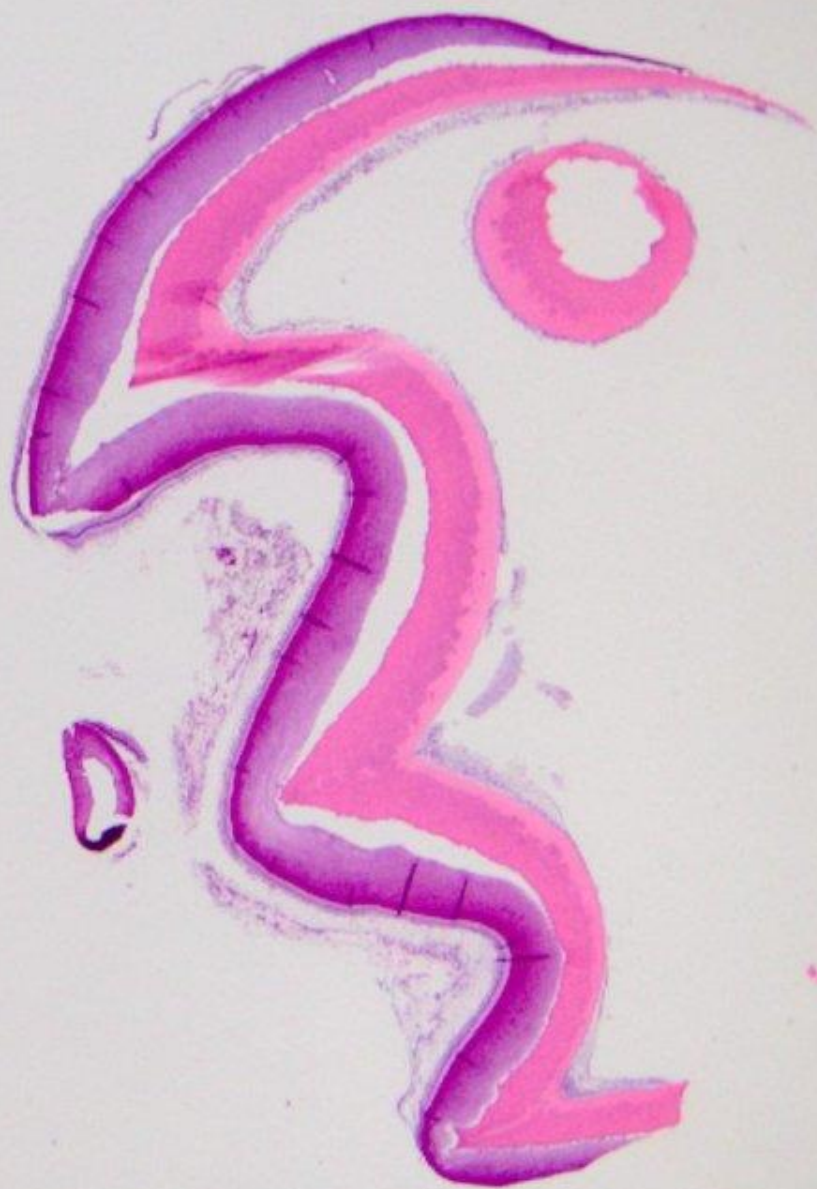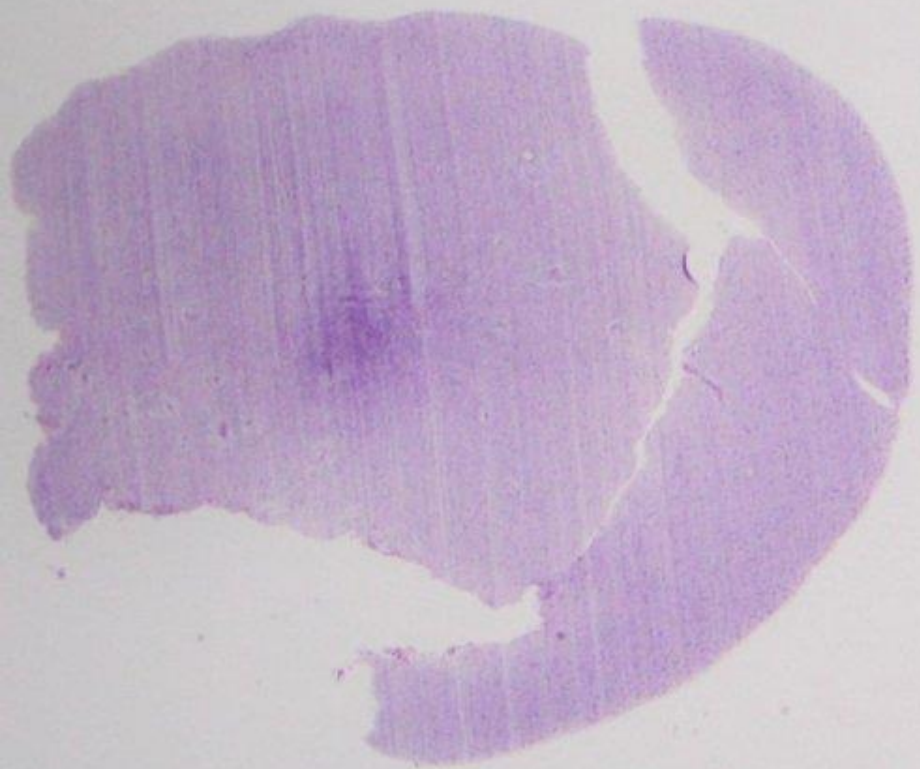




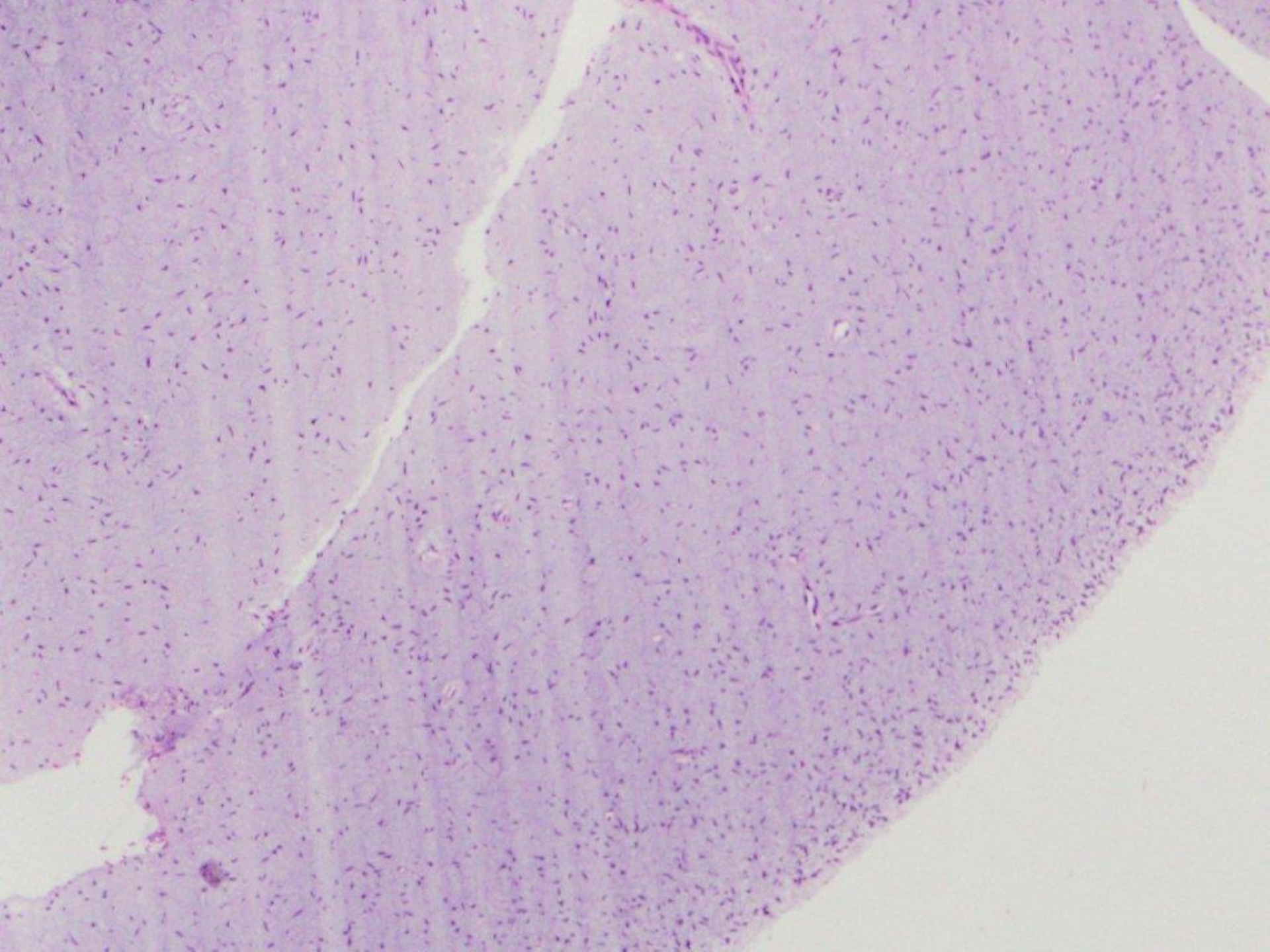


salivary duct cyst (floor of mouth)

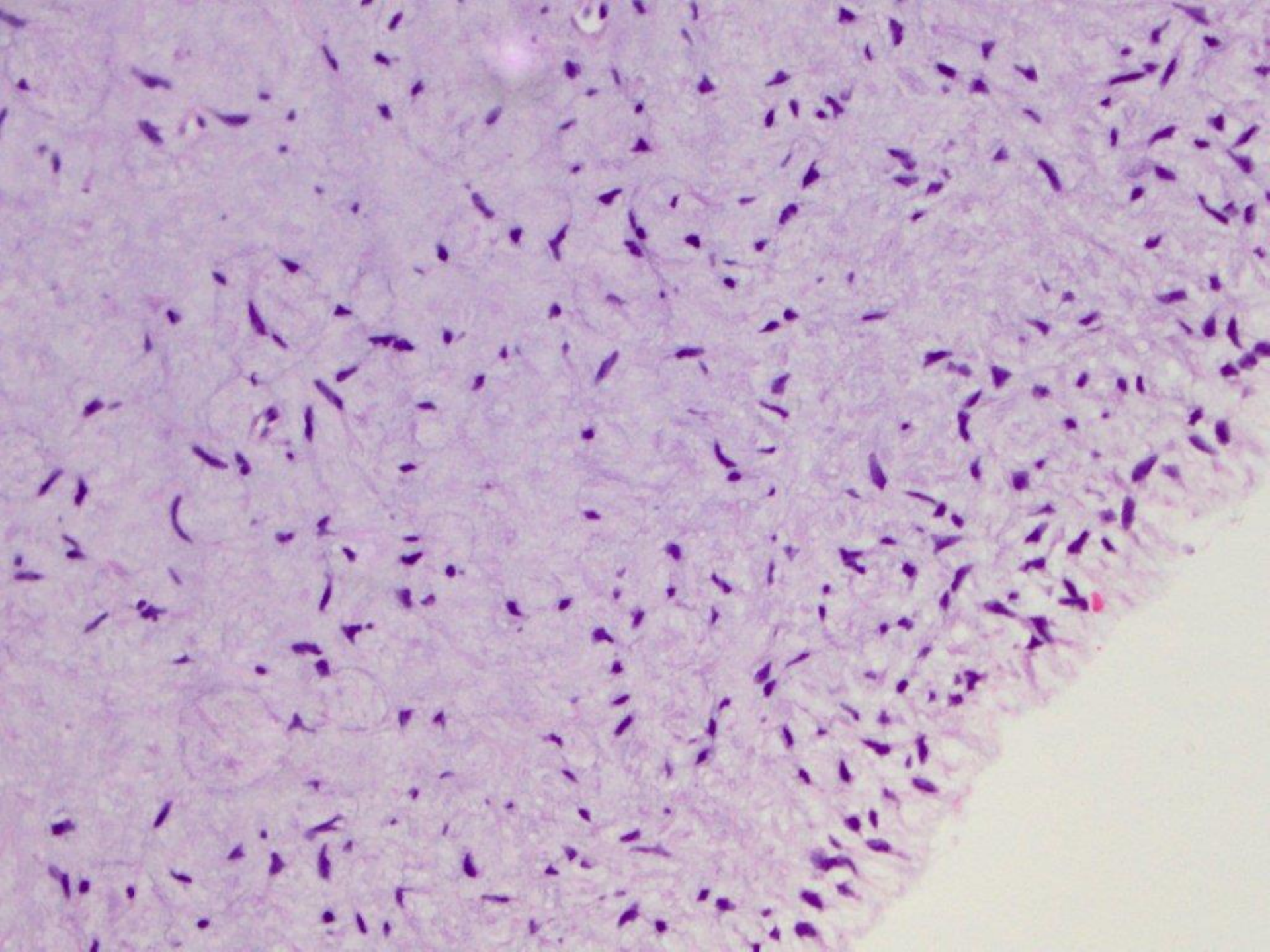




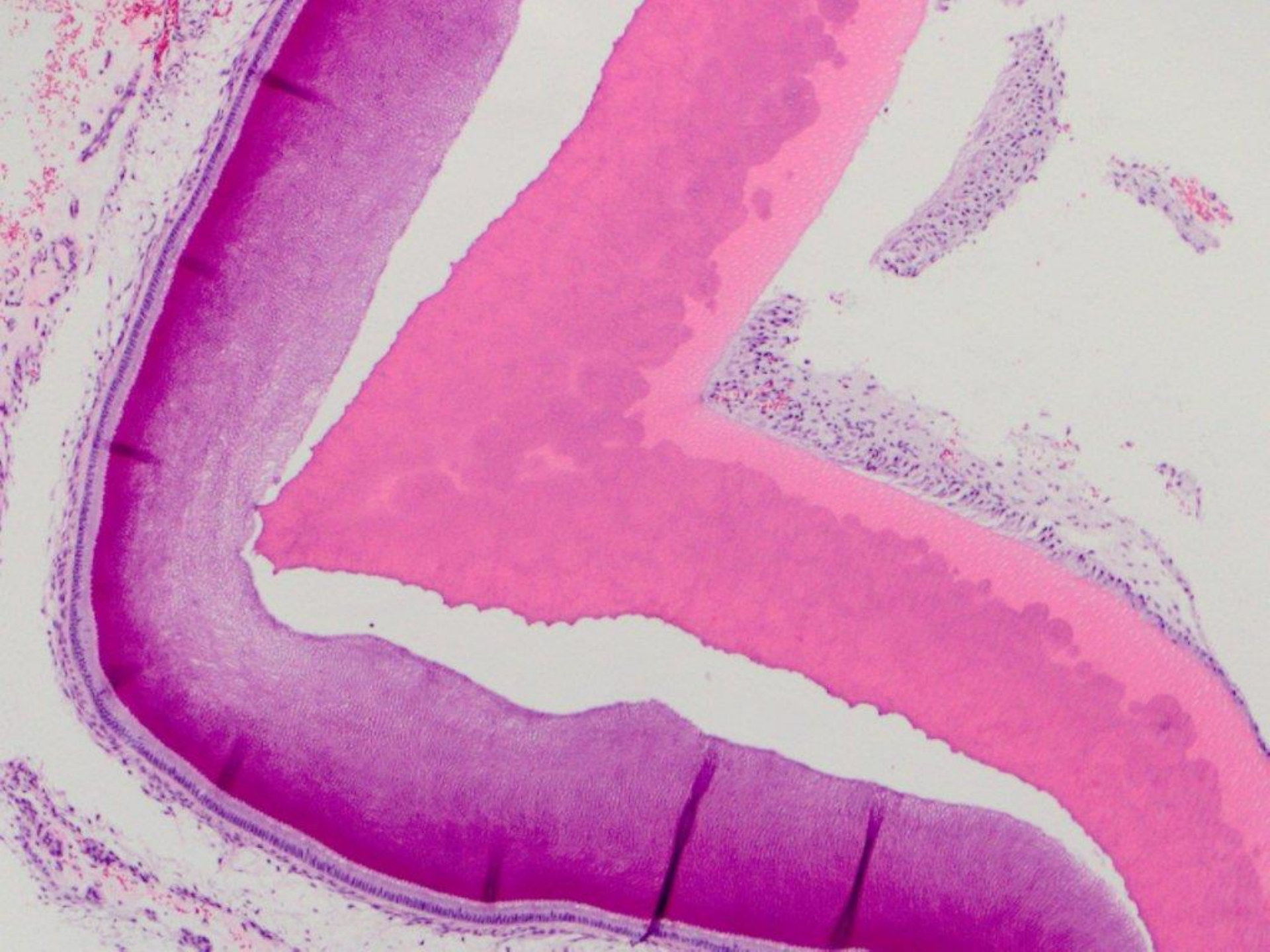




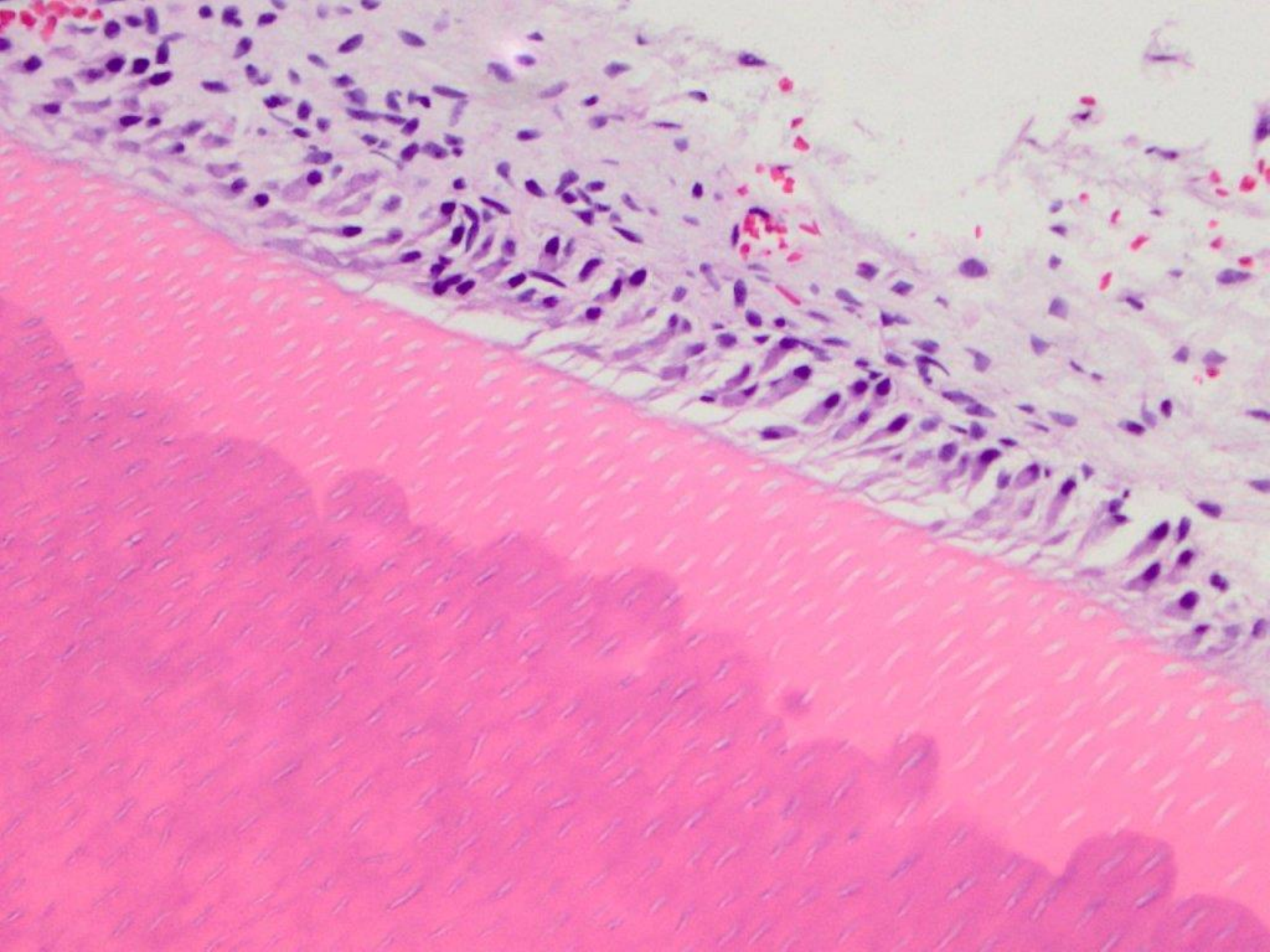




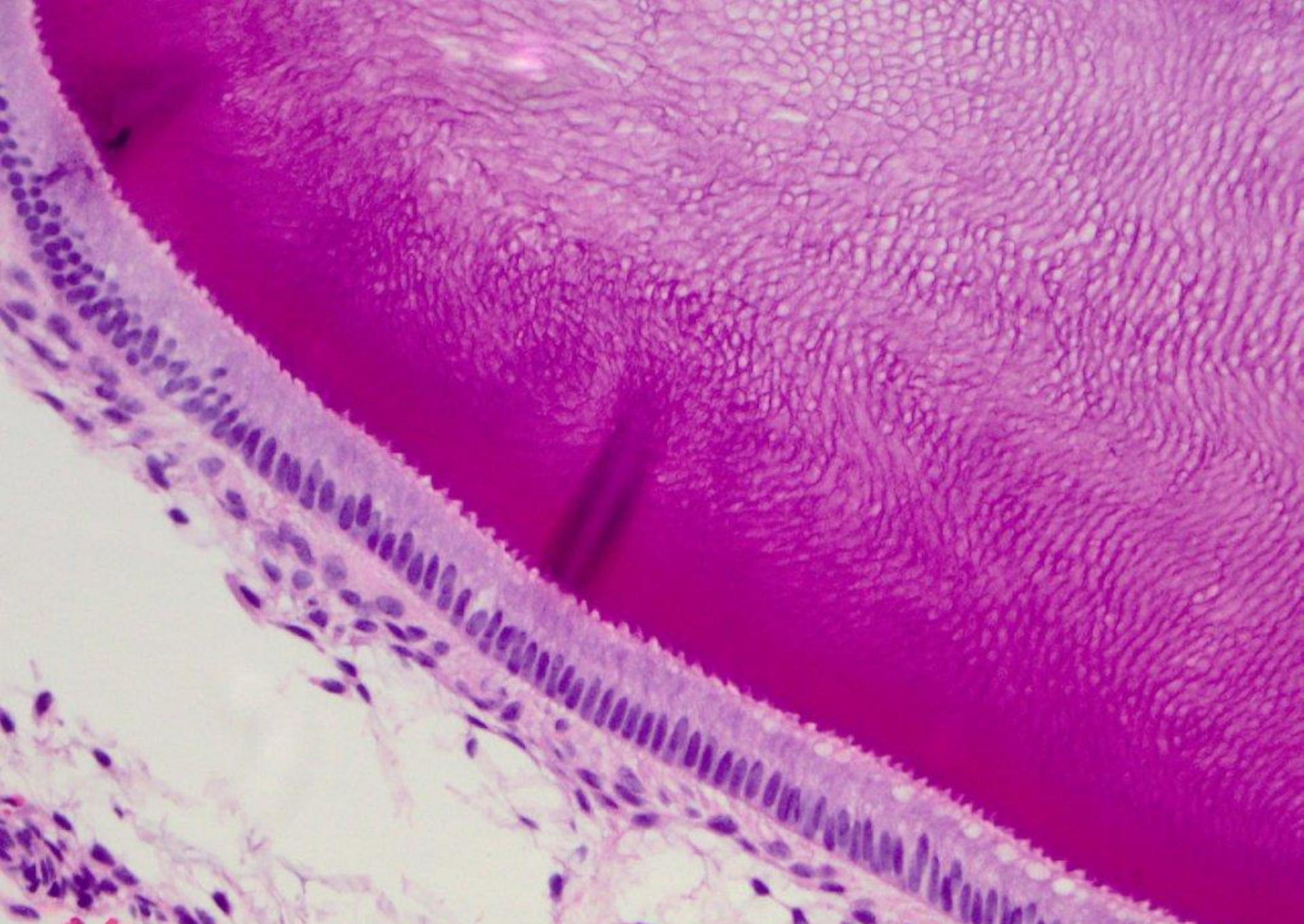






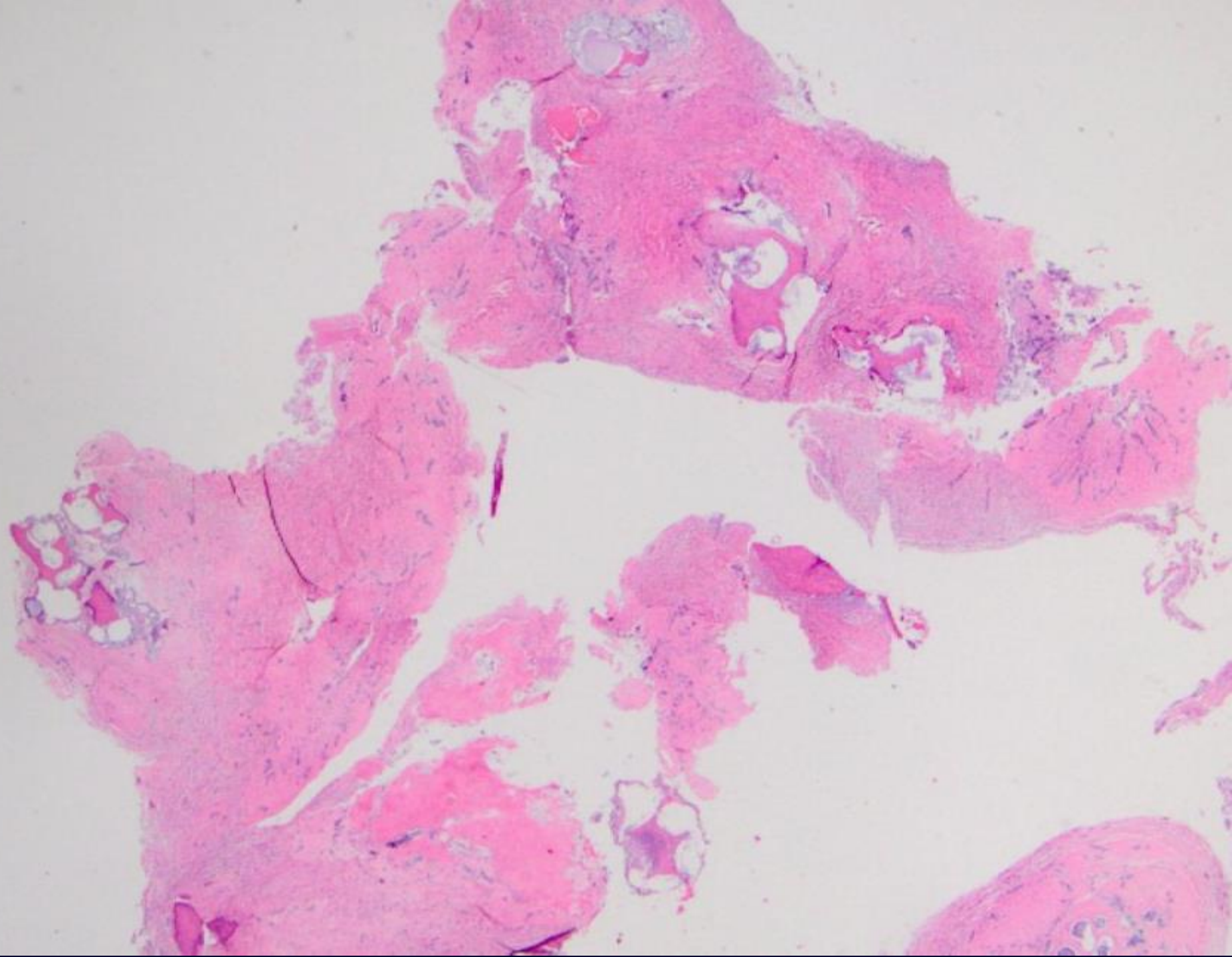




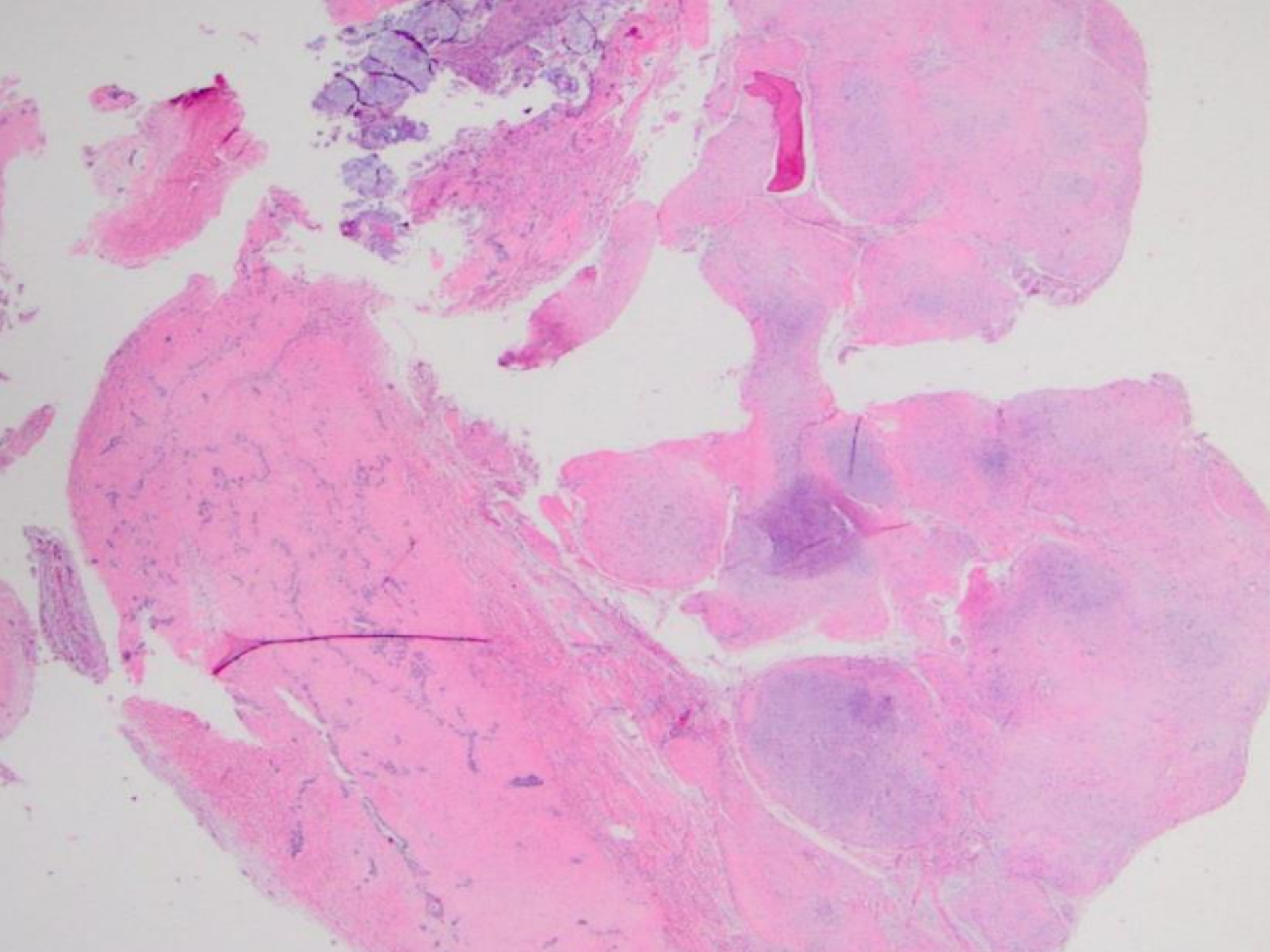


(compound) odontoma and primitive pulp

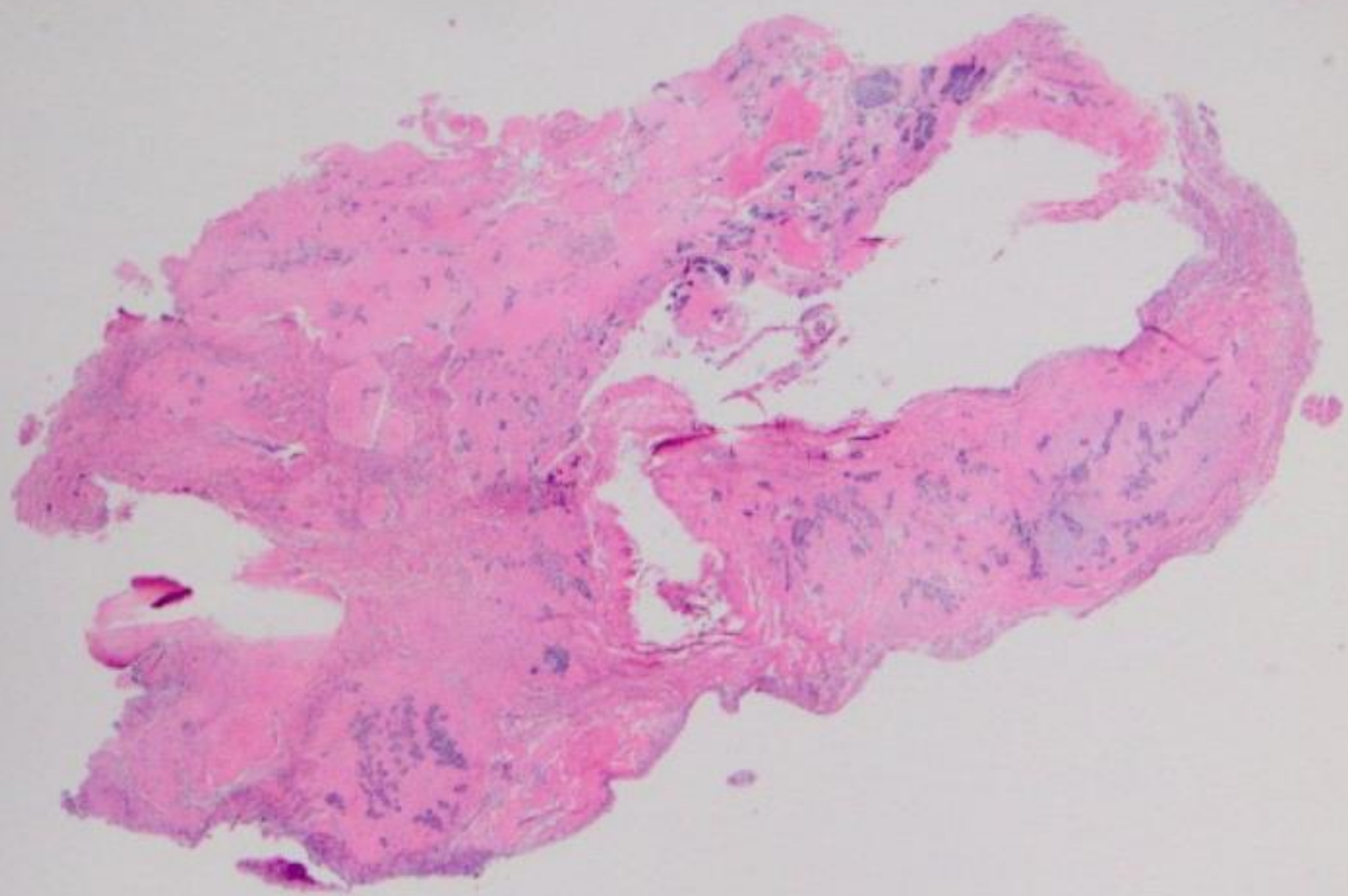




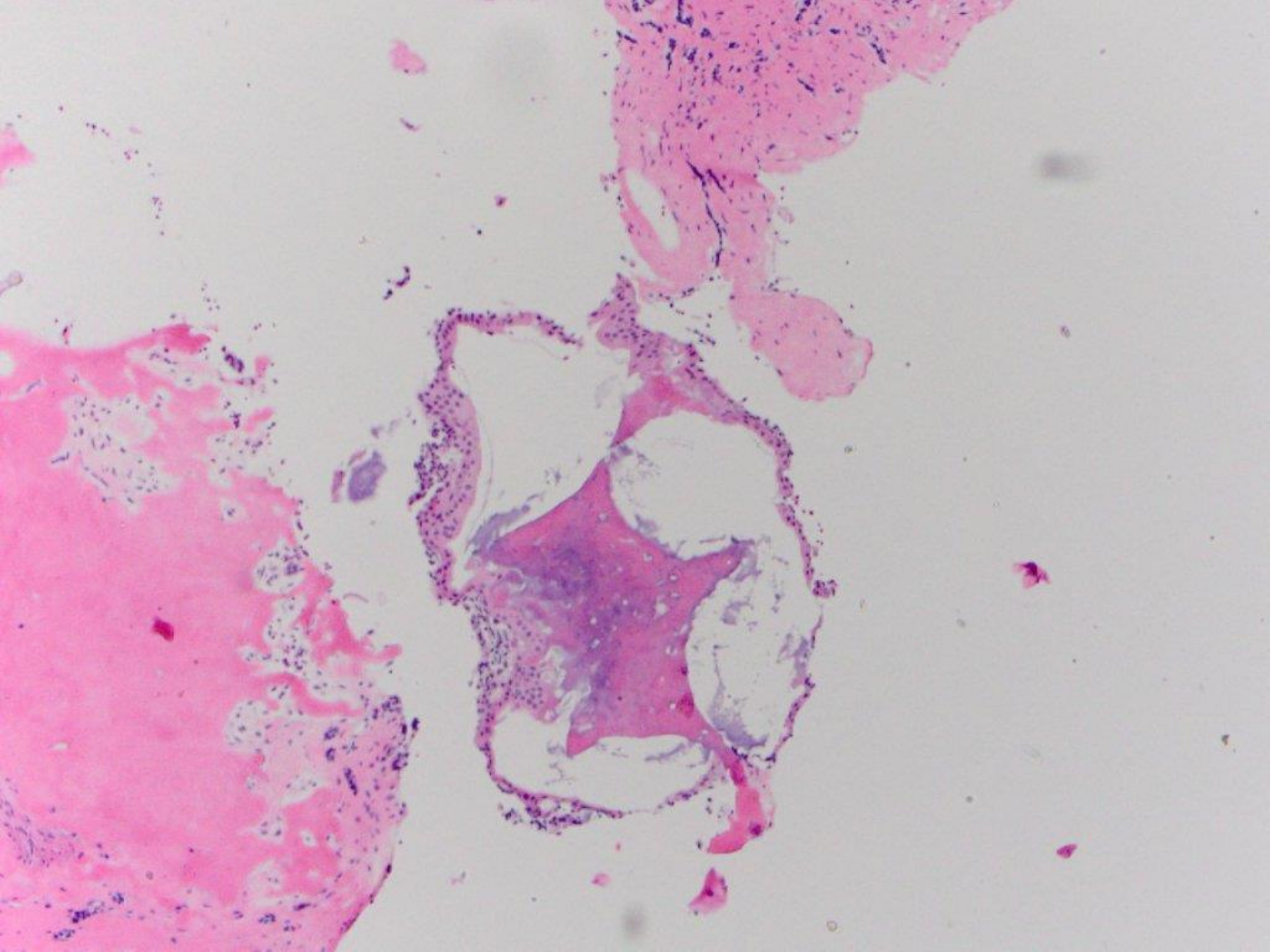




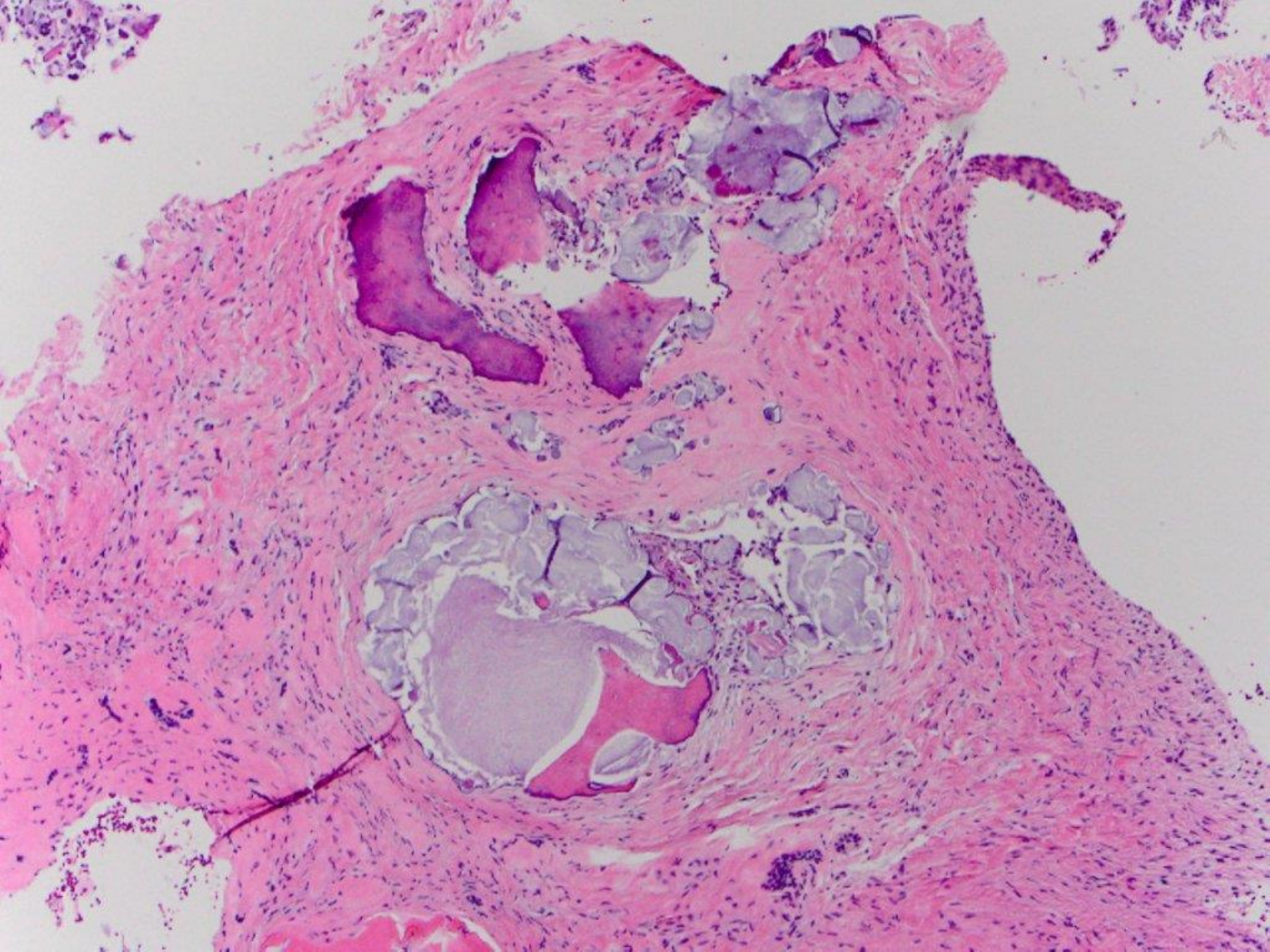




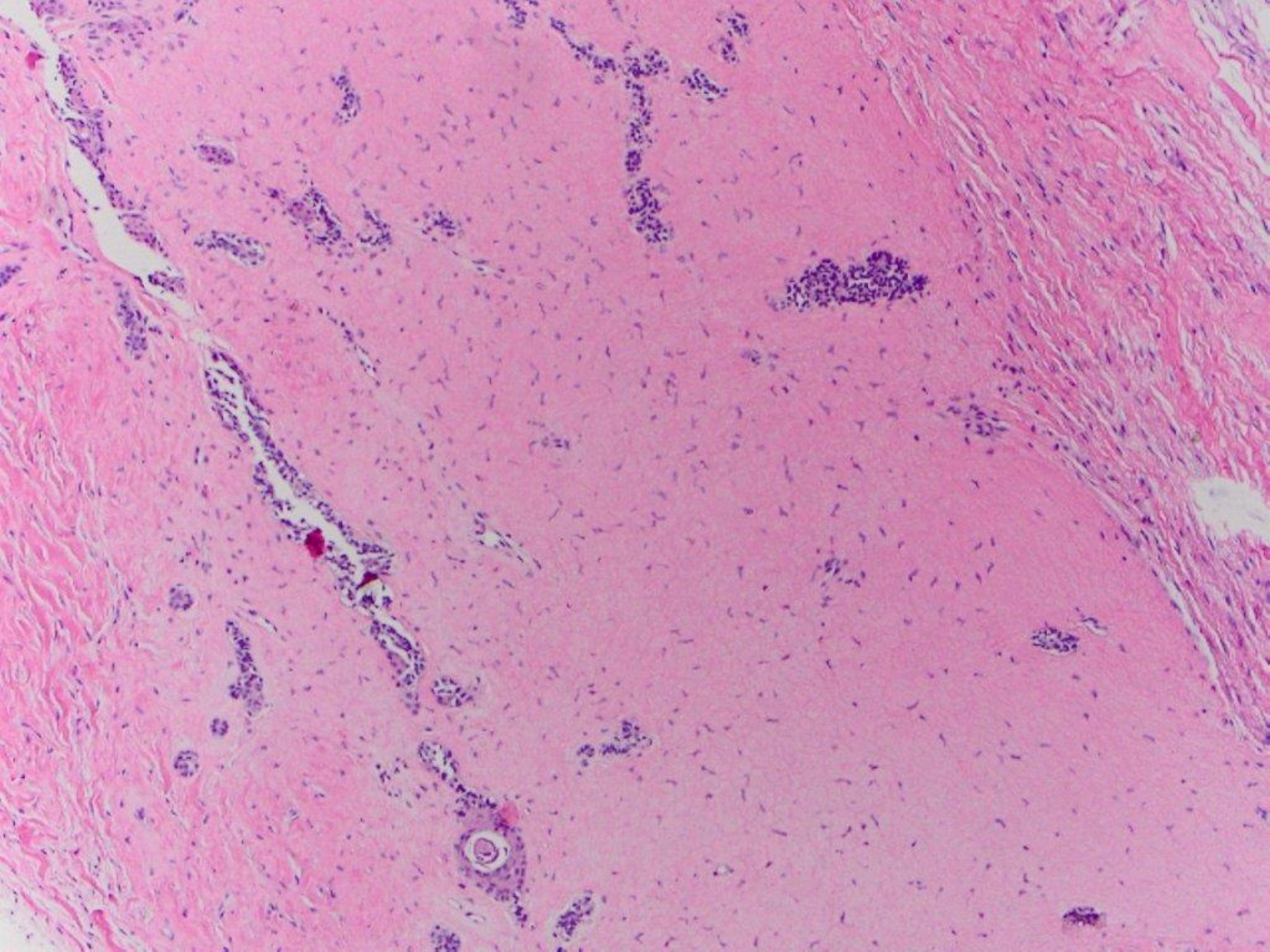




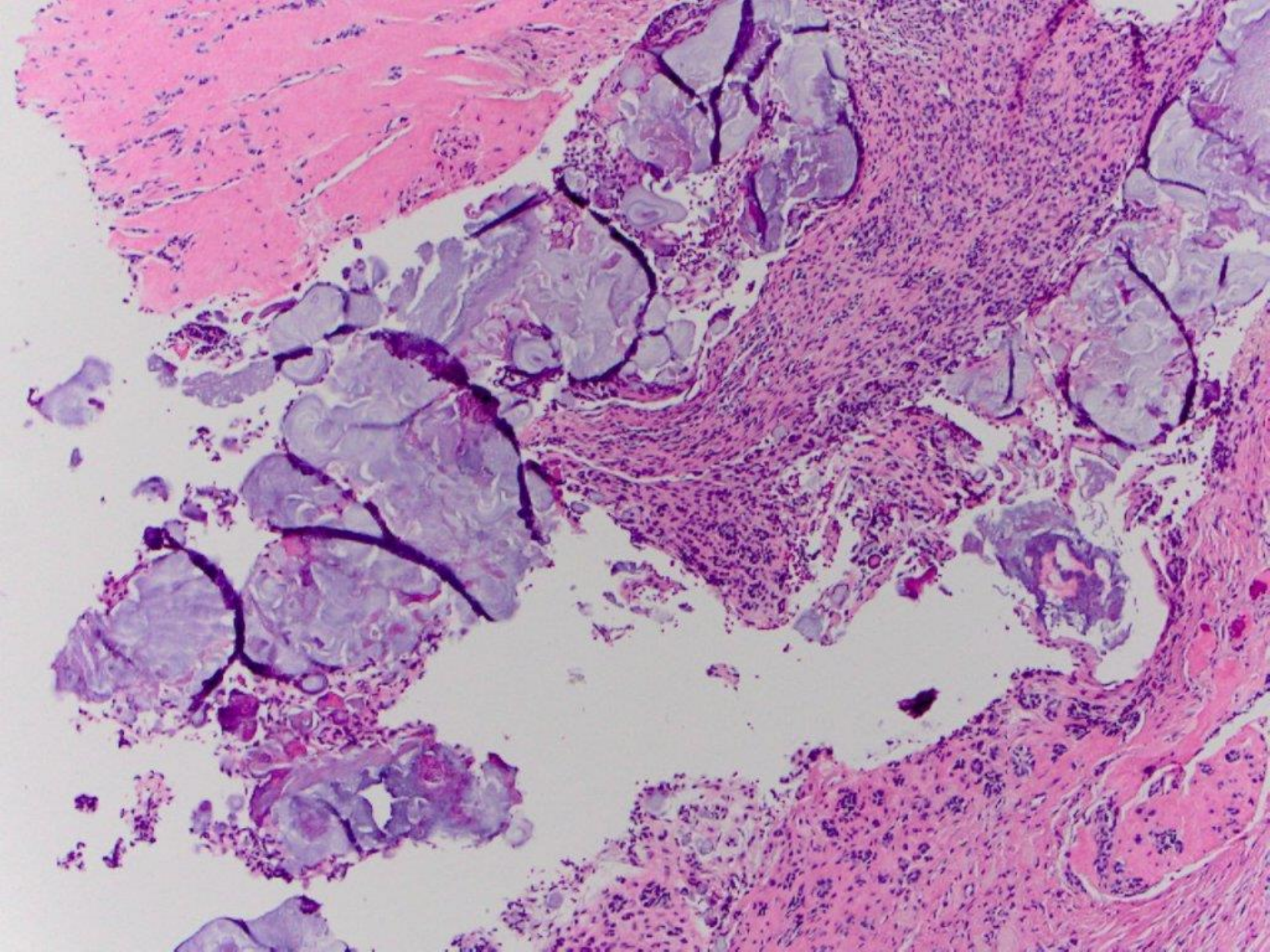




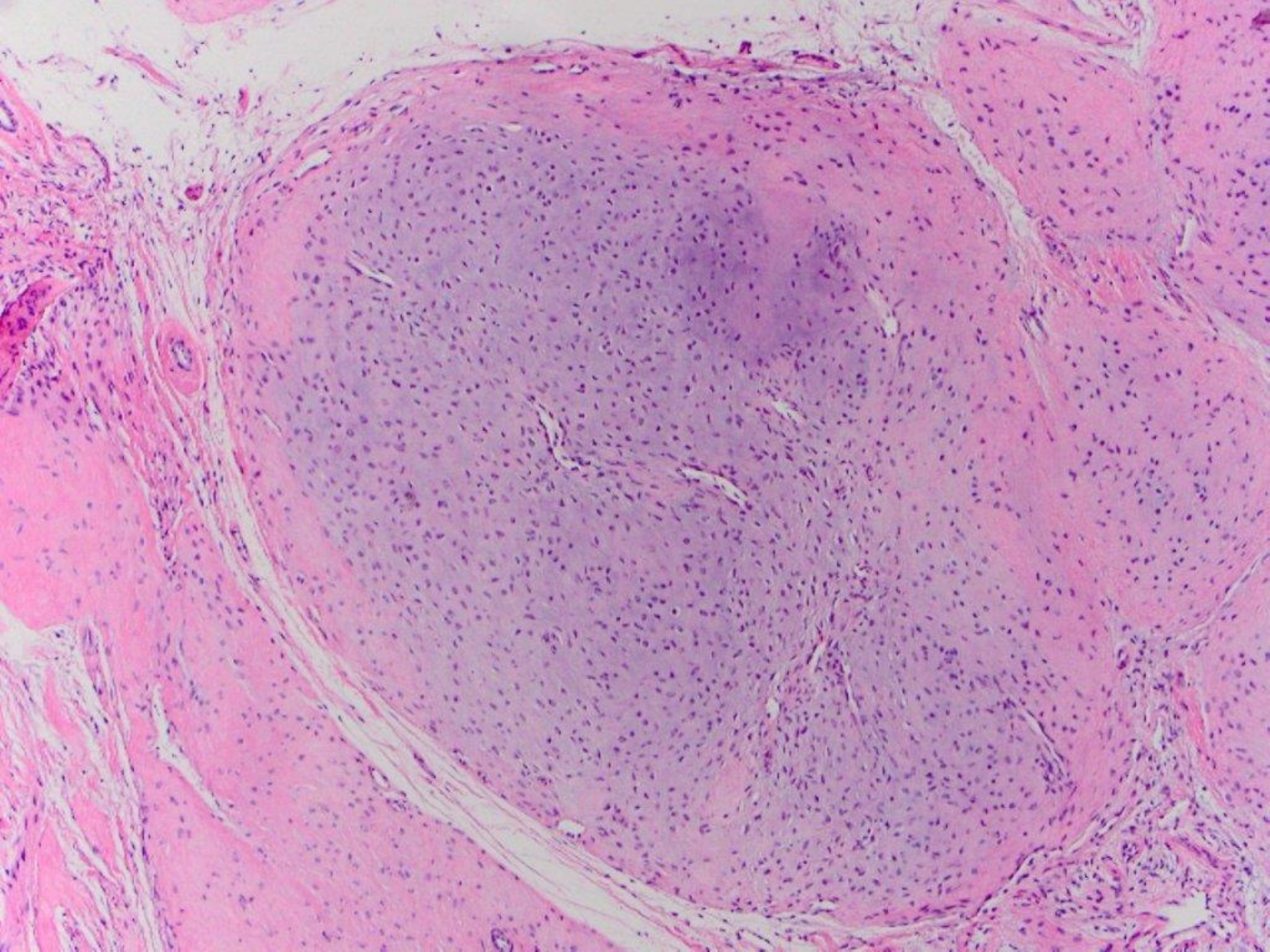




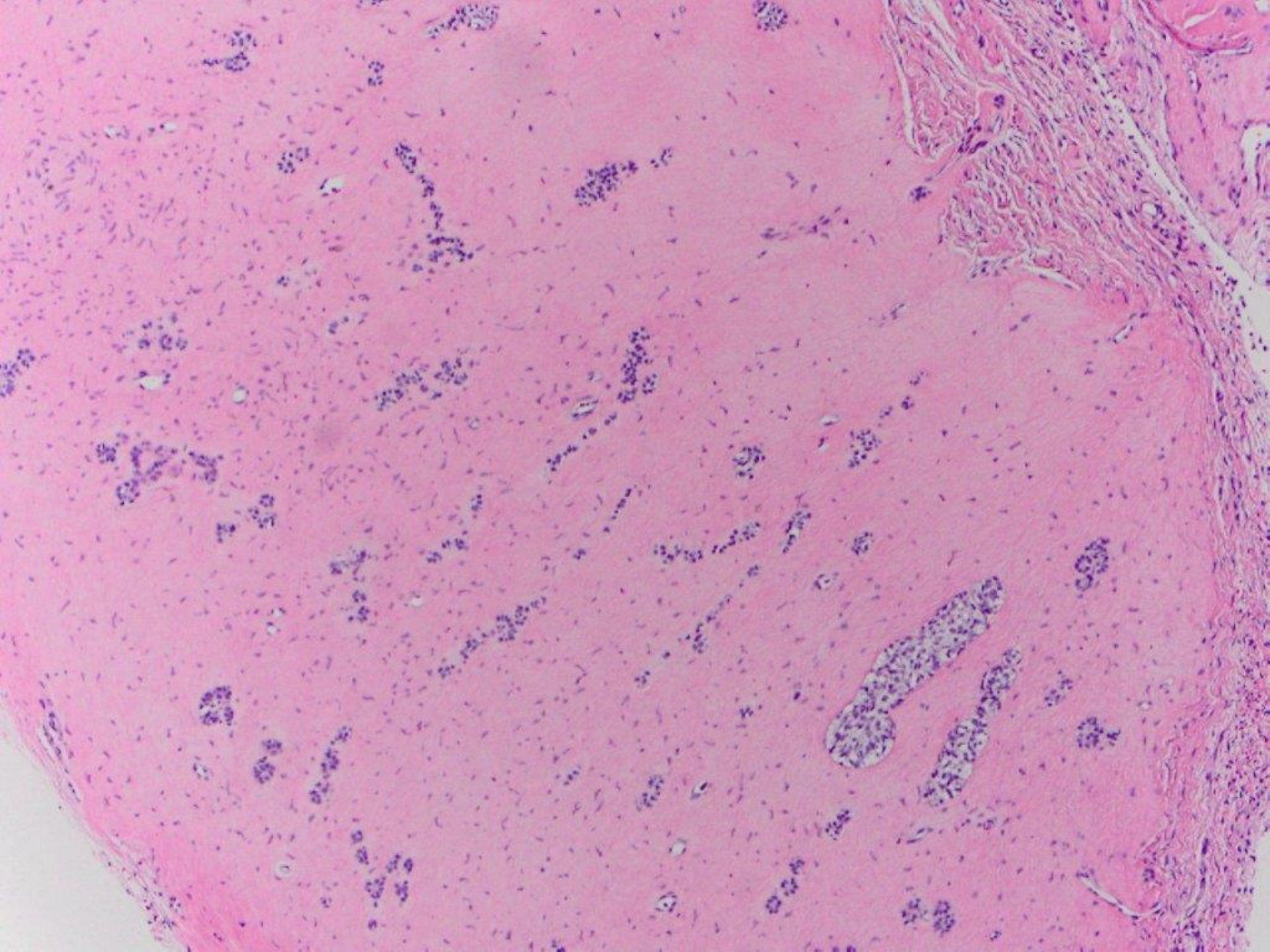




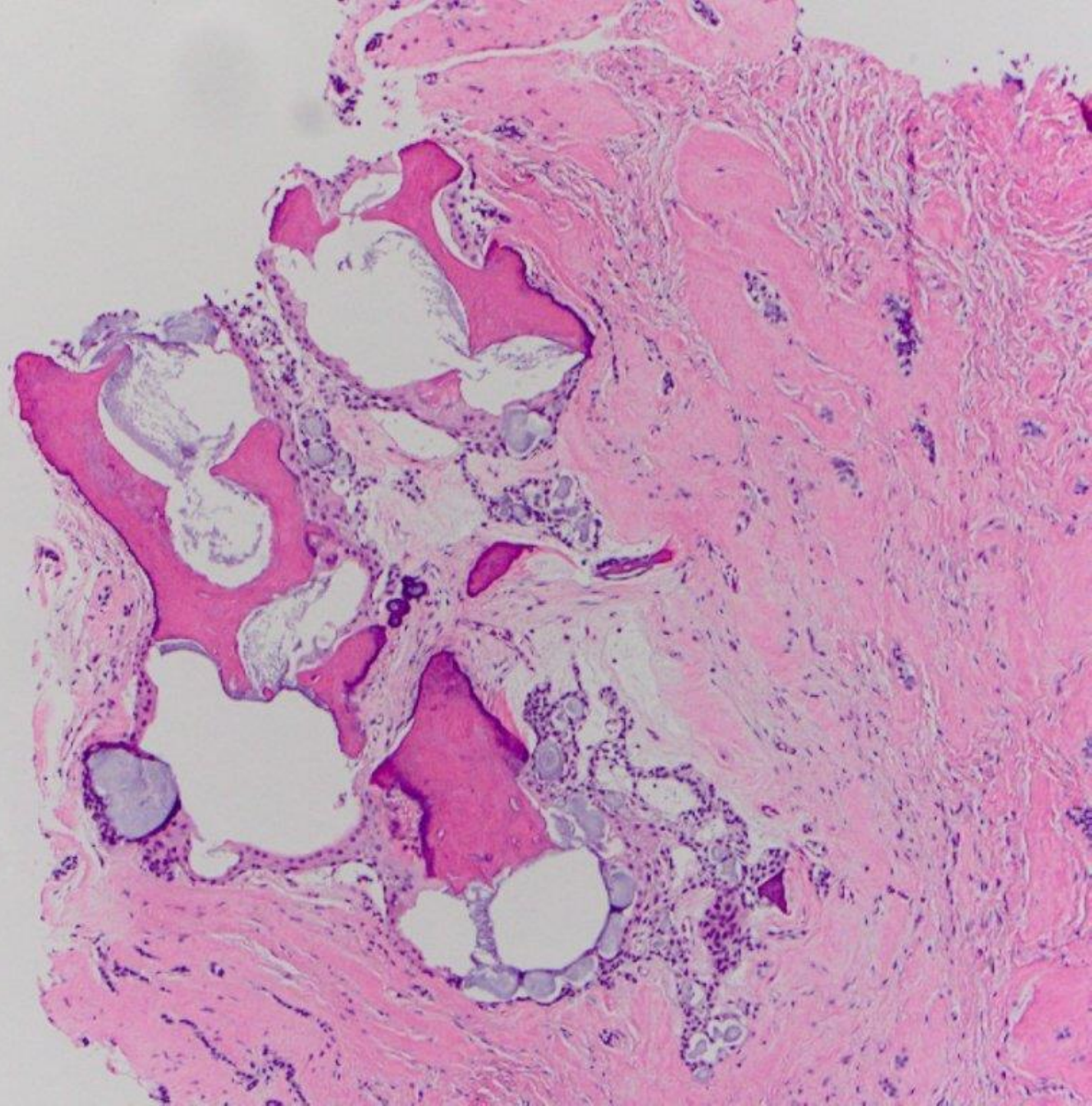




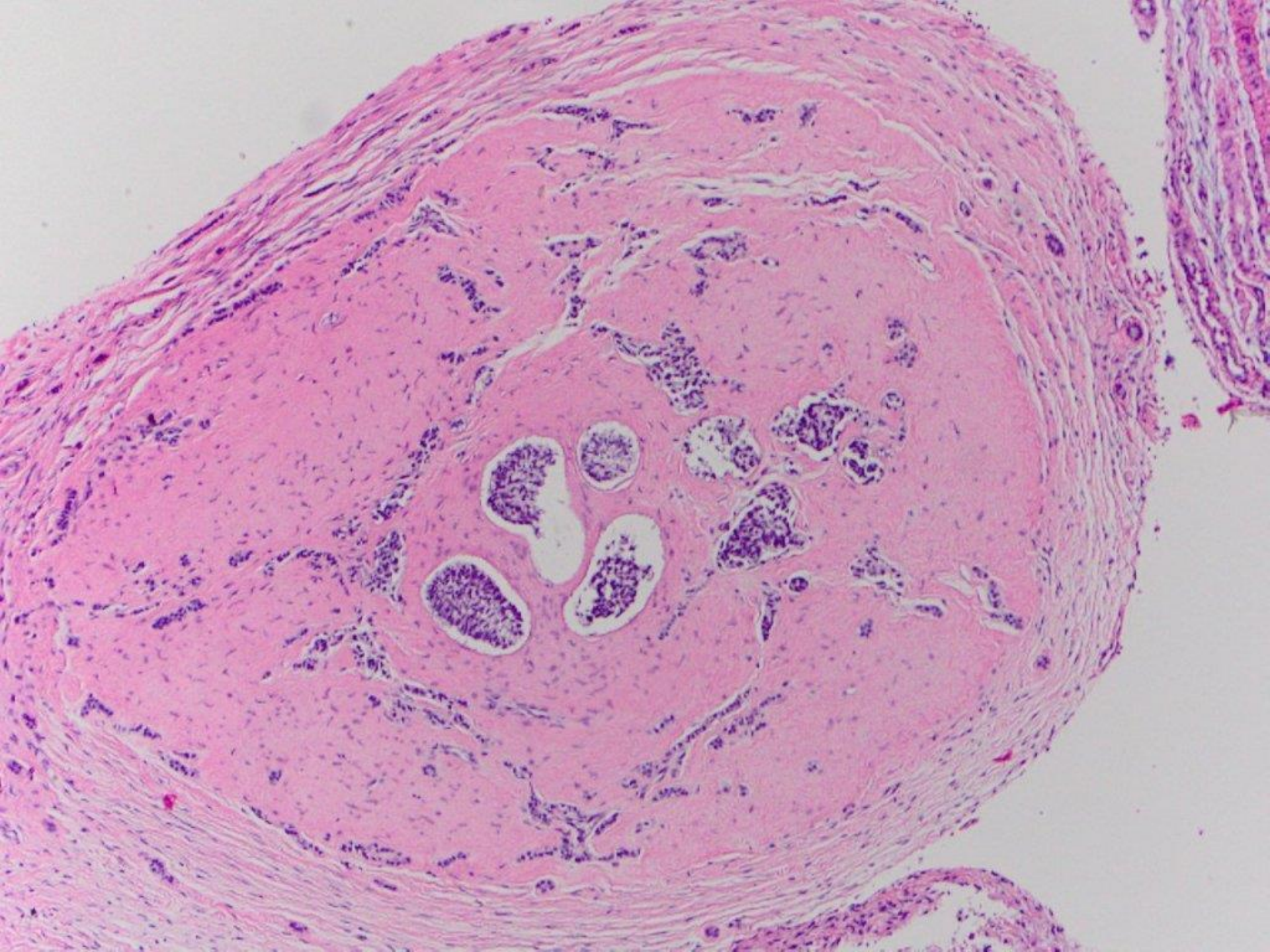




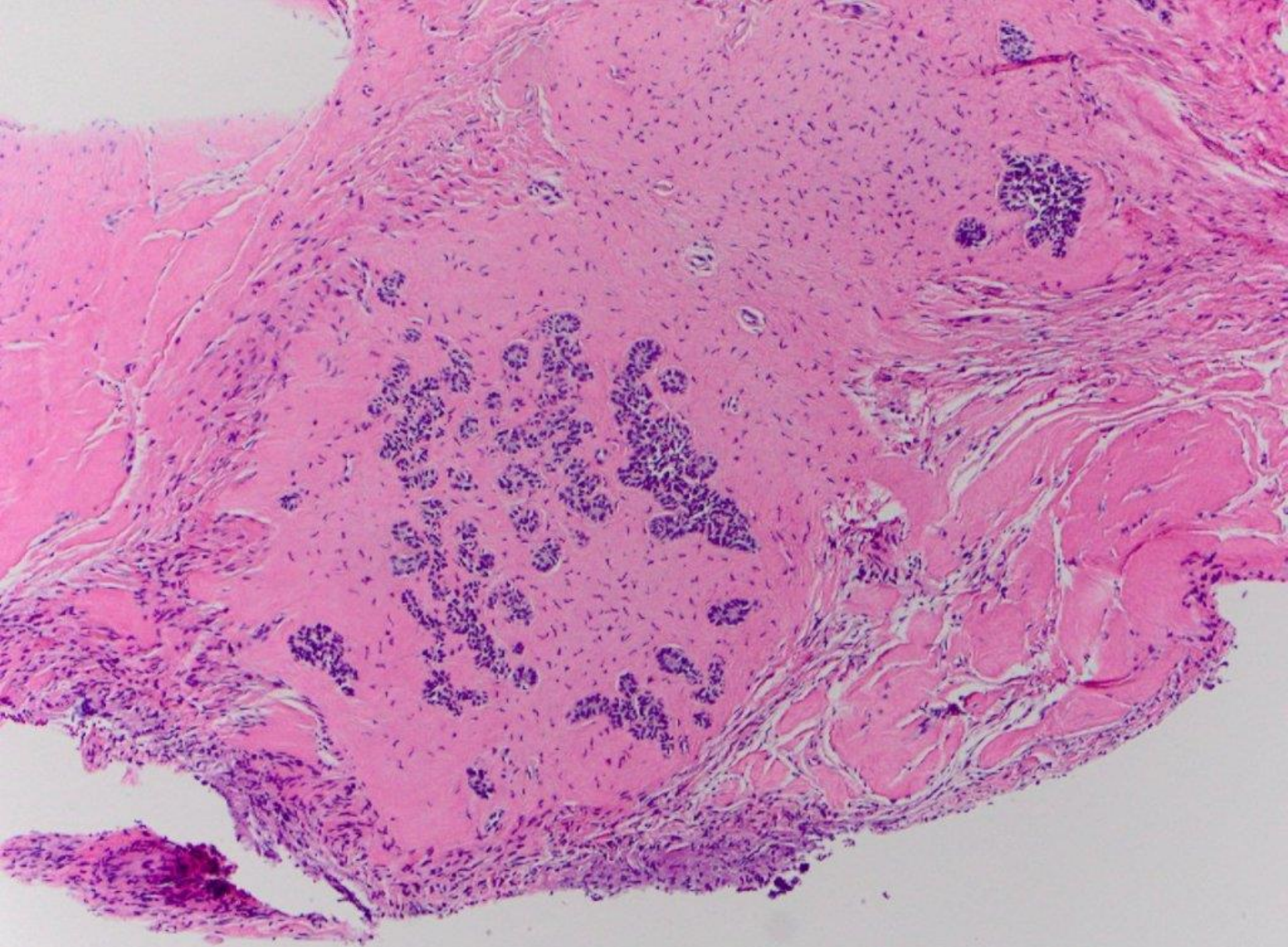




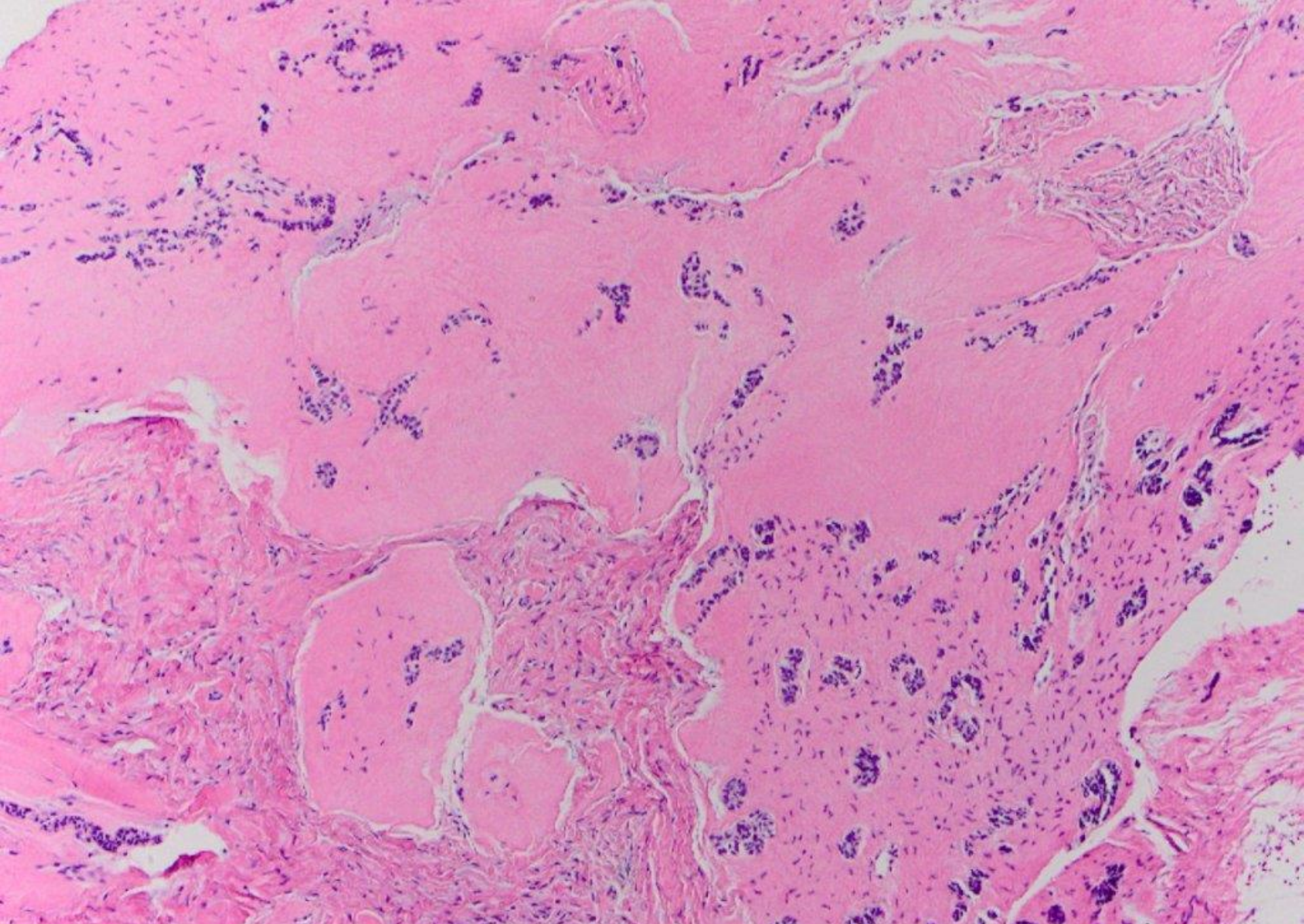






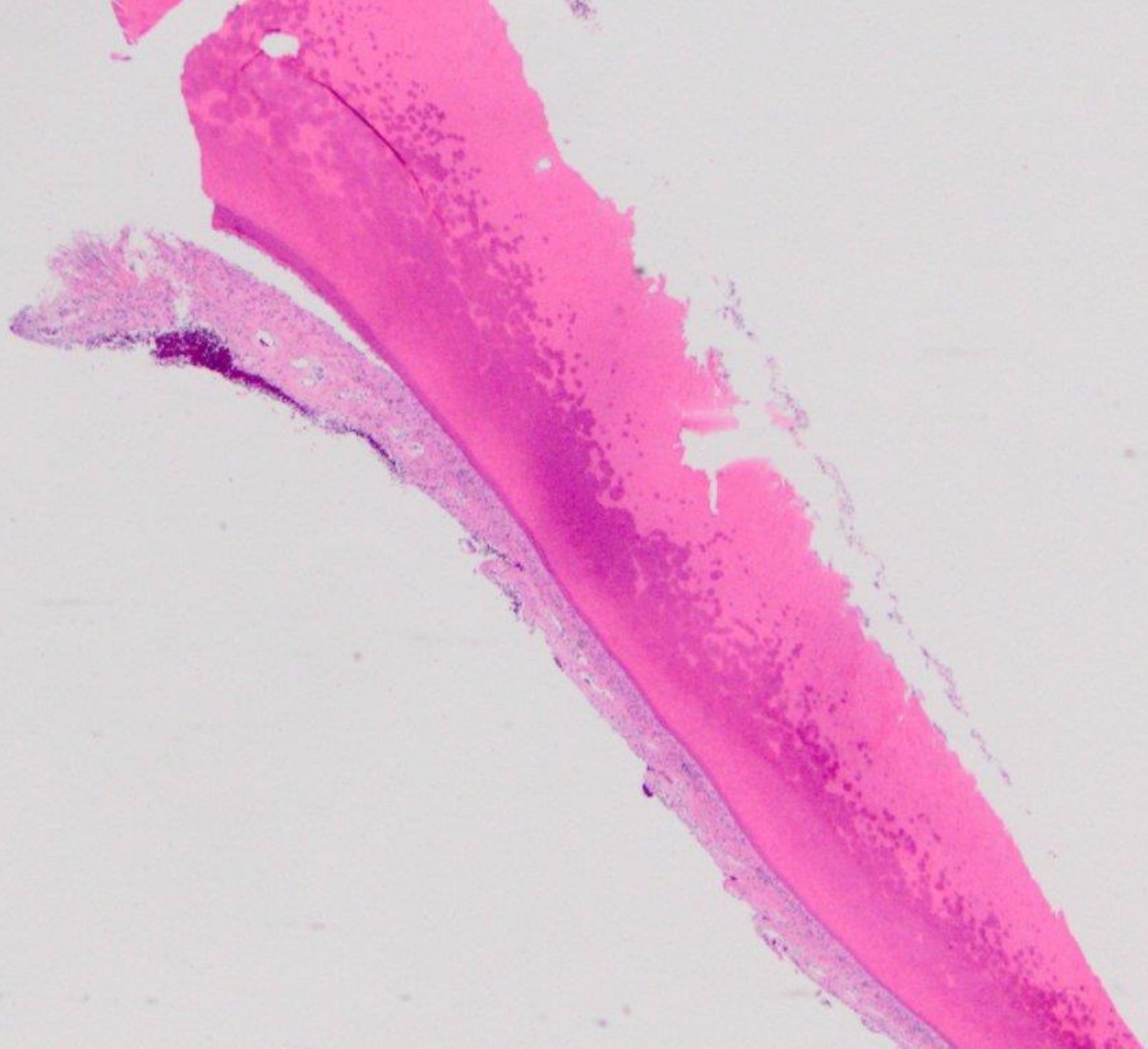




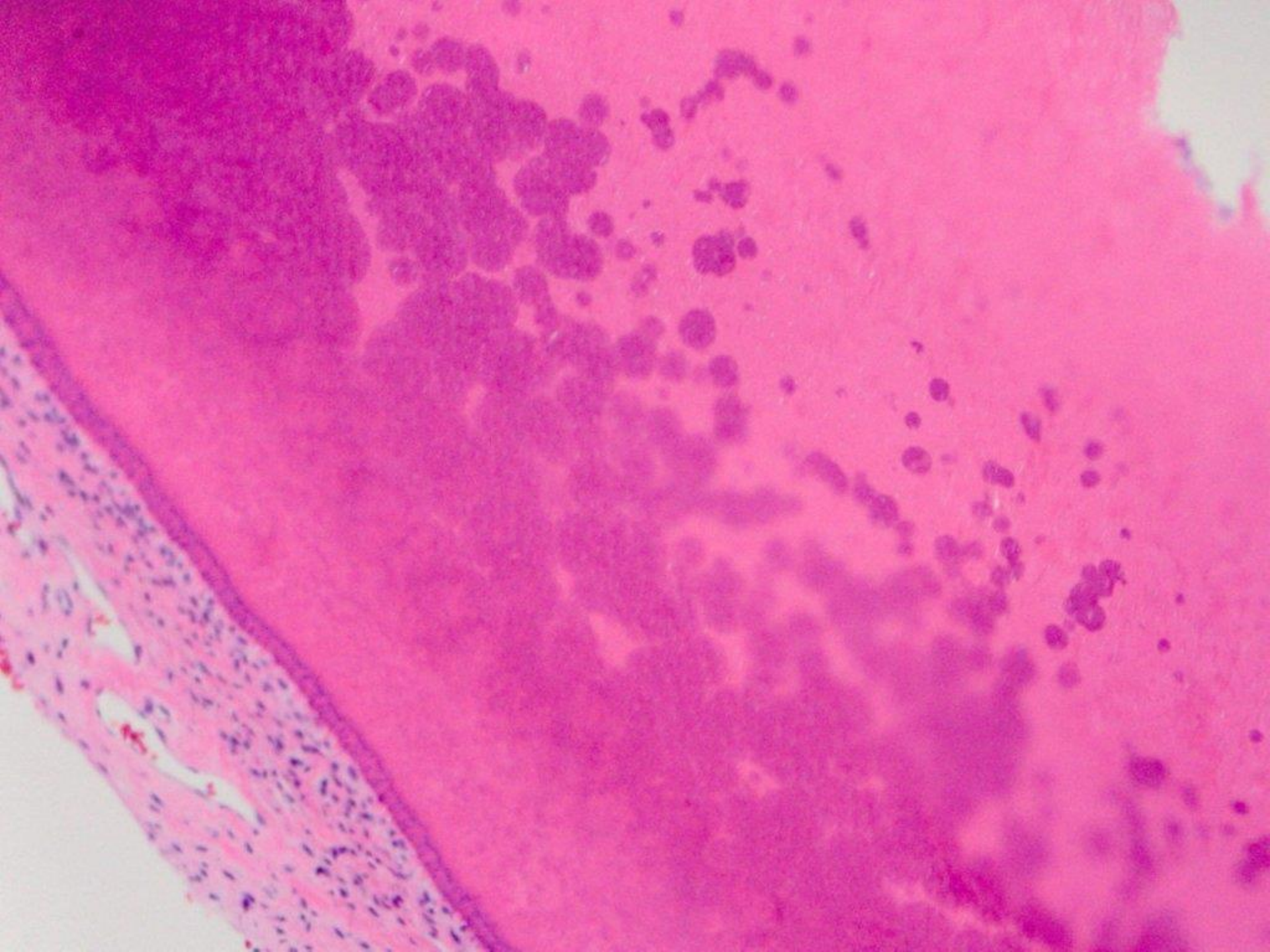


ameloblastic fibro-odontoma

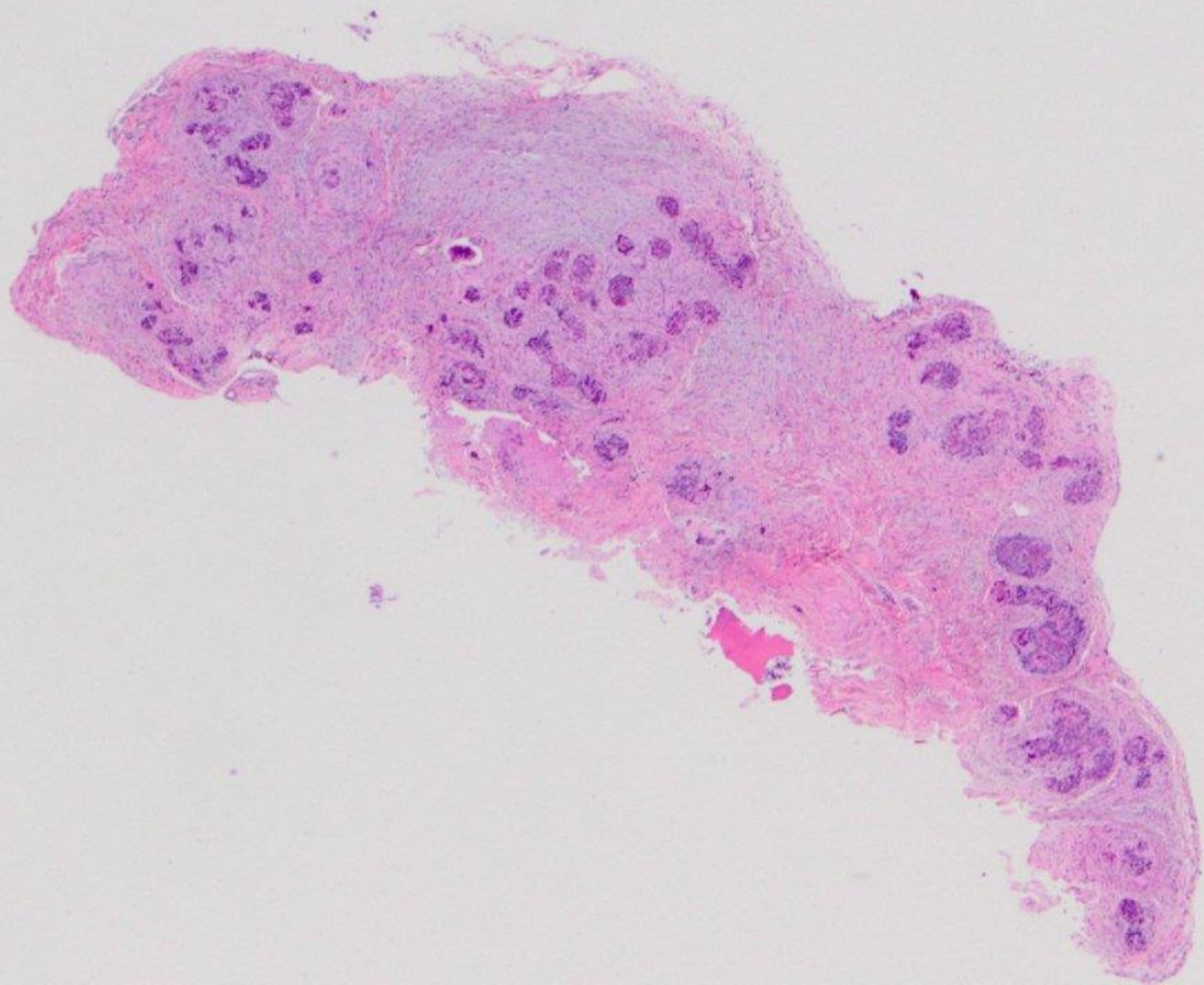




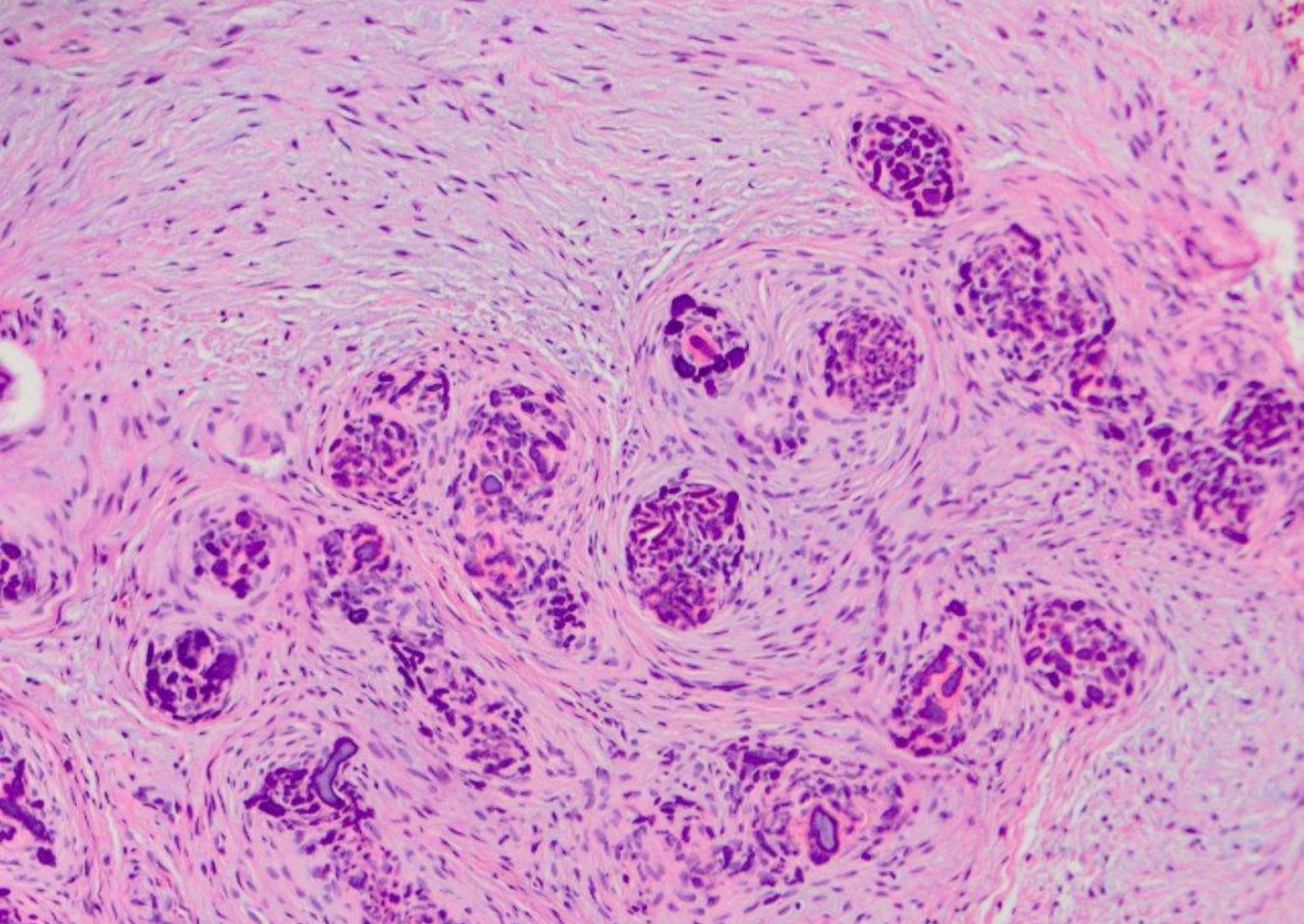












regional odontodysplasia